ONCOLOGY KNOWLEDGE HUB · FOR HEALTH PROFESSIONALS

Non-Small Cell Lung Cancer

A mini review for clinicians

For postgraduate residents (medical and radiation oncology, pulmonary medicine, thoracic and general surgery, medicine), practising clinicians and medical students

Dr. Haritha Chiramana

MD (Internal Medicine), DM (Medical Oncology)
Senior Medical Oncologist & Hemato-Oncologist
C.R. Reddy Cancer Center, C.R. Reddy Superspeciality Hospital
17/406, Old Post Office Road, near Leela Mahal Road, Nellore, Andhra Pradesh 524003
Phone 0861 232 5344 · WhatsApp +91 79896 42272
info@drharitha.co.in · drharitha.co.in

Dr. Haritha teaches oncology to postgraduates and medical students. Colleges and departments may write to info@drharitha.co.in for teaching sessions.

CONTENTS

01 At a glance
02 Clinical presentation, common traps & genetic causes
03 Screening, workup & staging essentials
04 Biomarkers that change treatment
05 Local therapy: surgery & radiotherapy
06 Systemic therapy: indications & options
07 Management algorithms
08 Survivorship, follow-up & reducing recurrence
09 Landmark trials
10 Practice pearls & pitfalls
11 Case vignettes: lines of management
12 References & guidelines

Cite as: Chiramana H. Non-Small Cell Lung Cancer: a mini review for clinicians. Oncology Knowledge Hub [Internet]. Nellore (India): drharitha.co.in; 2026 [updated 2026 Oct 9]. Available from: https://drharitha.co.in/professionals/lung-cancer · Free for education with attribution (CC BY-NC-ND 4.0).

Updated 9 October 2026. Educational summary written in our own words from current guidelines and primary trials; no drug doses; not advice for an individual patient. Verify current guidelines and Indian regulatory approvals before treatment decisions. Patients and families: please see the patient guides at drharitha.co.in.

Non-Small Cell Lung Cancer

Adenocarcinoma · squamous · EGFR · ALK · PD-L1 · Key points for clinicians · Last updated 9 October 2026

01 At a glance

- India records about 80,000 new lung cancers and nearly as many deaths each year (GLOBOCAN 2022): one of the commonest cancers in Indian men, and rising in women. Most patients (about three in four) are diagnosed at stage III–IV.
- Indian patients are often a decade younger than in Western series, and a substantial share (frequently a third or more of adenocarcinomas in Indian hospital series) have **never smoked**, especially women. Tobacco (cigarettes and bidis) still causes most lung cancers; biomass cooking smoke, second-hand smoke, outdoor air pollution, occupational dusts and previous TB add to the risk.
- Adenocarcinoma is now the commonest type. About half of Indian adenocarcinomas carry an actionable driver, chiefly *EGFR* (roughly one in three) and *ALK*. **Histology, stage, drivers and PD-L1** together decide treatment.
- Diagnosis is often delayed by months of empirical antituberculous treatment. Microbiological proof of TB, early CT and tissue are the single biggest changes a referring doctor can make.

Approximate share in Indian hospital series; adenocarcinoma has overtaken squamous, and "other" includes large-cell and NSCLC-NOS

Adenocarcinoma · ~50%	Squamous · ~28%	SCLC · ~14%	Other

Adenocarcinoma	Squamous cell	Small cell
NSCLC · TTF-1 positive	*NSCLC · p40 positive*	*Neuroendocrine · high Ki-67*
• Peripheral; never-smokers, women	• Central; cavitation; smokers	• Central, bulky nodes; heavy smokers
• Drivers common (EGFR ~1 in 3)	• Hypercalcaemia (PTHrP)	• SIADH, Cushing, Lambert-Eaton
• Brain, bone, pleura, adrenal spread	• Drivers rare: test if never-smoker	• Doubles in weeks; early brain spread
Test drivers first; targeted therapy or chemo-immunotherapy	**Chemo-immunotherapy; no pemetrexed or bevacizumab**	**Urgent platinum-etoposide + immunotherapy ± RT**

Figure 1. The working histological types. Histology and drivers, not just stage, decide treatment, so tissue matters from the first biopsy.

02 Clinical presentation, common traps & genetic causes

Who is at risk: ask about each of these

Exposure or condition	Approximate size of risk	Clinical note
Cigarettes, bidis, hookah	10–30 times never-smokers; lifetime risk in heavy smokers up to about 30%	Risk rises with pack-years and duration. After 15 years of abstinence it falls by roughly 80–90% but never to never-smoker level.
Second-hand smoke	Modest, dose-related	Matters most for women with long adult exposure at home.
Biomass and smoky-coal cooking smoke	Very large with smoky coal in Chinese cohorts; consistent excess with wood smoke	Linked to adenocarcinoma in never-smoking women; record years of indoor cooking on wood, dung or coal.
Previous pulmonary TB	About 1.5-fold in a pooled international analysis (ILCCO[1])	TB survivors are a risk group, not a reassurance: new symptoms need imaging, not another course of TB drugs.
COPD / emphysema	2–5-fold, independent of smoking	The commonest independent risk factor after tobacco itself.
Pulmonary fibrosis (ILD)	About 8–14-fold	Also raises the toxicity of every treatment (section 05).
Occupation and environment	Variable; strongly synergistic with smoking	Asbestos, silica, diesel exhaust, chromium, nickel, radon, and arsenic in groundwater (parts of eastern India).
Previous chest radiotherapy (Hodgkin lymphoma, breast cancer)	Several-fold, for decades	Highest in those who also smoke.
Family history in a first-degree relative	About 1.8-fold	Higher if the relative was young or several are affected.
Oestrogen–progestin menopausal therapy; high-dose beta-carotene supplements	More lung cancer deaths with combined hormone therapy (WHI[2]); higher incidence in smokers taking beta-carotene	Consider stopping hormone therapy after a lung cancer diagnosis; advise smokers against beta-carotene supplements. No supplement or drug prevents lung cancer.

How lung cancer presents

- A new or changed cough lasting more than 3 weeks (present in about half to three-quarters at diagnosis, most often with central squamous and small cell tumours), haemoptysis, breathlessness (about a quarter to two-fifths), chest pain, loss of weight and appetite. Many cancers are asymptomatic and found as a nodule on a CT done for another reason.
- Local spread: hoarseness (left recurrent laryngeal nerve), stridor, dysphagia, superior vena cava obstruction (facial and arm swelling, dilated chest veins), a pleural effusion that keeps refilling.
- **Pancoast (superior sulcus) tumour**: shoulder and arm pain, C8–T1 weakness and Horner syndrome, often labelled “frozen shoulder” or cervical spondylosis.
- Paraneoplastic syndromes: hypercalcaemia (squamous, PTHrP), SIADH with hyponatraemia (about one in ten small cell cancers), ectopic ACTH and Lambert-Eaton myasthenia (small cell), clubbing and hypertrophic

osteoarthropathy (NSCLC), and venous thromboembolism.

- First presentation with metastases is common (about one in five NSCLCs already has bone metastases, with pain and a raised alkaline phosphatase): bone pain or fracture, headache, seizure or weakness, jaundice, an adrenal mass, a supraclavicular node, or spinal cord compression.

Common traps

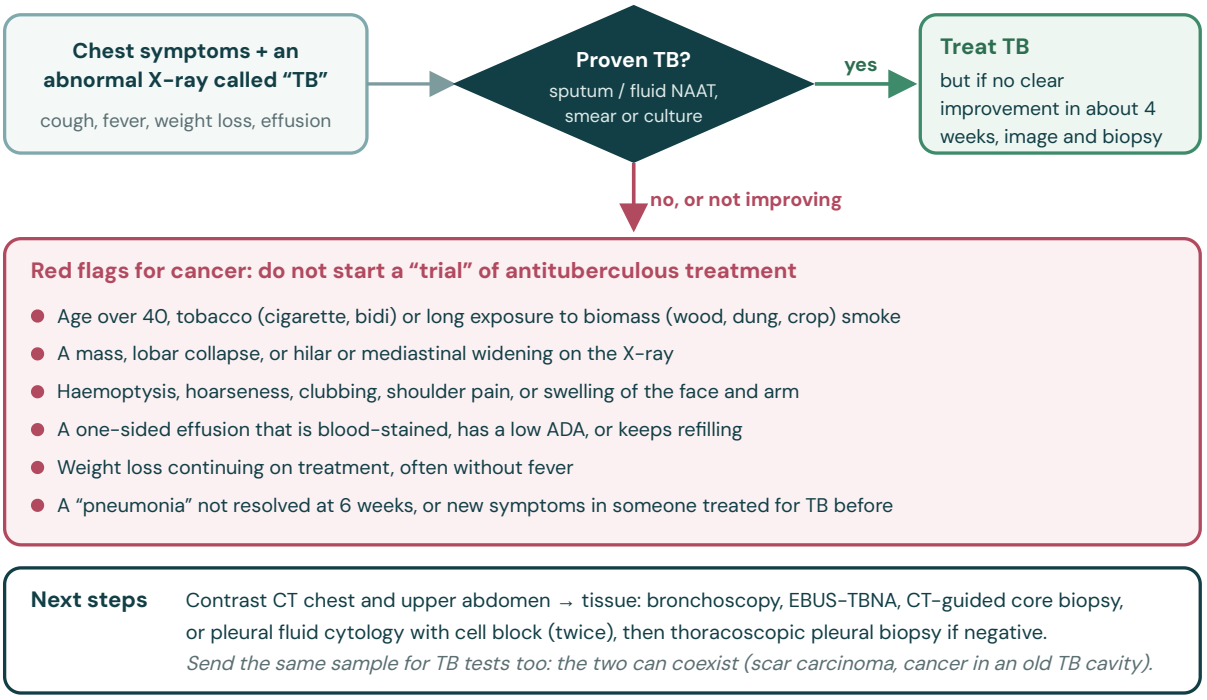

Figure 2. The tuberculosis trap. Empirical antituberculous treatment without microbiological proof is one of the commonest causes of delayed lung cancer diagnosis in India.

Trap	What to do instead
Antituberculous treatment started on an X-ray alone, without sputum NAAT, smear or culture	Prove TB microbiologically. If unproven or not improving within about 4 weeks, contrast CT and tissue (Figure 2).
A lymphocytic exudative effusion called "tubercular"	Low ADA, blood-staining or rapid refilling point away from TB: send two cytology samples with a cell block, then thoracoscopic biopsy.
A non-resolving "pneumonia" or "COPD exacerbation" in a smoker	Repeat imaging at 6 weeks; CT and bronchoscopy if not clear. Post-obstructive collapse hides a central tumour.
"Chest X-ray normal, so no cancer"	The X-ray misses a meaningful minority of cancers (central, small, behind the heart or diaphragm). Persistent symptoms or haemoptysis need CT.
"Young, female, never smoked: it cannot be lung cancer"	Never-smokers develop adenocarcinoma, often *EGFR*- or *ALK*-driven. Investigate symptoms the same way.
Shoulder pain treated for months as frozen shoulder	Apical view or CT chest; MRI of the brachial plexus for suspected Pancoast tumour.
Hoarseness assessed by ENT, cord palsy found, nothing further	Left vocal-cord palsy needs CT of the chest (aortopulmonary window).
A biopsy reported as "granulomatous inflammation" from a growing mass	TB and cancer coexist (scar carcinoma, cancer in an old cavity). Repeat or larger biopsy if the picture does not fit.

Trap	What to do instead
PET-positive nodes assumed to be metastatic, or PET-positive nodule sent for SBRT without tissue	Granulomatous disease is PET-avid in India. Confirm nodes with EBUS before denying surgery, and obtain tissue before SBRT whenever feasible.
Squamous carcinoma in a never-smoker not tested for drivers	Test: drivers occur in squamous and adenosquamous tumours of never- or light smokers.
Rapid progression on an EGFR or ALK inhibitor	Re-biopsy: transformation to small cell (about 3–10%) needs platinum–etoposide, not another TKI.

Genetic causes

- Lung cancer is mostly **acquired**. Having a first-degree relative with lung cancer raises risk about 1.8-fold, partly through shared smoking and household smoke, more so if the relative was young.
- *EGFR*, *ALK* and other drivers found in the tumour are **somatic**: they are not inherited, and relatives do not need testing. Reassure families, who often ask.
- Rare germline syndromes: germline *EGFR* T790M (familial adenocarcinoma in never-smokers), *TP53* (Li-Fraumeni). Refer for genetic counselling when tumour NGS shows a likely germline pattern (variant allele frequency around 50% in a young patient or a striking family history).
- *EGFR* mutations are more common in Asian patients, women and never-smokers: a population pattern, not a family one.

SHARE WITH PATIENTS: WARNING SIGNS THAT GET MISSED

Plain-language myth pages written for patients and families. Send them from the clinic to reinforce what you discussed.

- 🖨 Telugu–English handout: lung cancer warning signs (తెలుగు · English)
- 🖨 Telugu–English handout: TB or lung cancer? Only tests can tell (తెలుగు · English)
- Blood in the sputum always means TB?
- If I had TB before, my new cough must be TB again?
- A long-lasting cough is always due to infection, allergy or TB?
- A normal chest X-ray completely rules out lung cancer?
- If there is no blood in the sputum, it can't be lung cancer?
- Lung cancer always causes a persistent cough?
- Only smokers get lung cancer?
- Women rarely get lung cancer?
- Only elderly people get lung cancer?

03 Screening, workup & staging essentials

Screening and early detection

Group	Evidence	What to advise
Current or former heavy smokers (USPSTF: age 50–80, ≥20 pack-years, quit within 15 years)	Low-dose CT (LDCT) cut lung cancer deaths by 20% in **NLST**[3] and by about 24% in men in **NELSON**[4].	Offer only with shared decision-making and where a nodule pathway exists (radiology reporting with Lung-RADS, tumour board, access to biopsy). Combine with smoking cessation.
India	No Indian randomised trial; no national LDCT programme. TB and fungal granulomas cause many false positives.	Be cautious: expect more indeterminate nodules, follow-up scans and biopsies than Western data suggest. Never treat a screen-detected nodule as TB or cancer without proof.
Never-smokers (including biomass exposure or family history)	Screening studies in East Asian never-smokers find many early, slow-growing cancers; overdiagnosis is a real concern.	Not recommended outside research. Investigate symptoms promptly instead.
Tests that are not screening	Chest X-ray screening did not reduce mortality; sputum cytology, tumour markers and PET-CT have no screening role.	Do not offer them as “lung check-ups”.

- **Harms of LDCT**: false positives (about one in four rounds in NLST, though Lung-RADS reduces this), overdiagnosis, radiation from follow-up scans, and complications of invasive work-up.
- **Lung-RADS** standardises screening reports: categories 1–2 are negative (next yearly scan), 3 and 4A/4B/4X are positive with set follow-up or work-up, and an “S” flags a significant incidental finding (adrenal, kidney, thyroid). One low-dose CT gives about 1 mSv, roughly a third of a year of natural background radiation.
- **When to stop**: once the person has not smoked for 15 years, or life expectancy or fitness for treatment is limited. Screening works best inside an organised programme with a coordinator, tracking of follow-up scans and smoking-cessation support. Blood-based early-detection tests are not for use outside trials.
- **Timing in India**: screen only when the person has been free of respiratory infection for about 12 weeks; scanning during TB or pneumonia manufactures false positives. Autofluorescence bronchoscopy and sputum cytology are not screening tests.
- **Incidental nodules** (not screening): follow the Fleischner Society rules (Figure 3). A solid nodule stable for 2 years, or with benign calcification, needs no further work-up.

Incidental nodule on CT in an adult aged 35 or over (not screening, no known cancer, not immunocompromised)

Solid nodule

< 6 mm
No routine follow-up (high risk: optional CT at 12 months)

6–8 mm
CT at 6–12 months, then 18–24 months

> 8 mm
CT at 3 months, PET-CT, or biopsy

Ground-glass (pure)

< 6 mm
No routine follow-up

≥ 6 mm
CT at 6–12 months to confirm it persists, then every 2 years to 5 years

Part-solid

< 6 mm
No routine follow-up

≥ 6 mm
CT at 3–6 months; if persistent with a solid part ≥ 6 mm, treat as suspicious

Benign signs: central, diffuse, laminated or popcorn calcification; fat within (hamartoma); stable solid size for 2 years.
In India, healed TB and fungal granulomas are common and PET-avid: a PET-positive nodule still needs tissue before surgery or SBRT.
Screening (low-dose CT) uses Lung-RADS categories instead; nodules in known cancer are managed by the oncology team.

Figure 3. The incidental nodule (Fleischner Society 2017, simplified for a single nodule). Size, density and risk decide the interval; growth or a new solid part changes the plan.

SHARE WITH PATIENTS: SCREENING AND TESTS

Plain-language myth pages written for patients and families. Send them from the clinic to reinforce what you discussed.

- Every lung nodule must be removed by surgery straight away?
- Everyone should have a yearly CT scan to check for lung cancer?
- Every lung nodule seen on a CT scan is cancer?
- A PET scan can confirm lung cancer without a biopsy?
- A lung biopsy makes cancer spread?
- Air pollution cannot cause lung cancer?

Diagnosis and staging

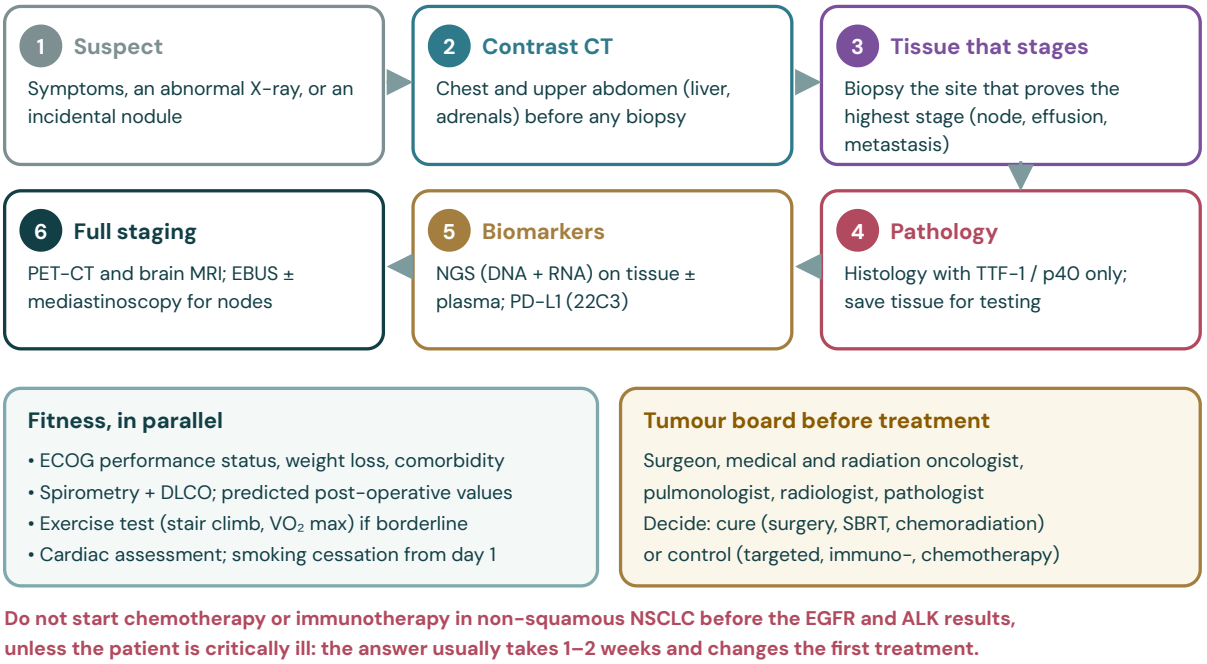

Figure 4. From suspicion to treatment plan (follow the numbers). One well-planned biopsy should give the diagnosis, the stage and enough tissue for biomarkers.

- **CT first**: contrast CT of the chest and upper abdomen before any biopsy, so the biopsy can be planned to prove the highest stage. Baseline blood tests: blood count, electrolytes, calcium, alkaline phosphatase, liver enzymes, creatinine and albumin; an abnormal calcium or alkaline phosphatase points to bone disease.
- **Choose the biopsy that stages**: EBUS-TBNA of an enlarged node (diagnosis and N stage together), pleural fluid for an effusion, or the suspected metastasis (supraclavicular node, liver, adrenal, bone; not the brain) rather than the primary. Otherwise: conventional bronchoscopy for large central tumours, navigational or radial-EBUS bronchoscopy or CT-guided core biopsy (higher pneumothorax risk) for peripheral lesions. Sputum cytology only for central tumours when nothing else is possible. Core biopsies and cell blocks are better than smears for molecular testing.
- **Pathology**: classify as adenocarcinoma, squamous, small cell or other using as few stains as possible (TTF-1, p40; neuroendocrine markers if small cell is suspected). "NSCLC-NOS" should be uncommon. Reserve tissue for biomarkers.
- **PET-CT** for every patient being considered for curative treatment (it upstages about one in five). Where PET-CT is not available, contrast CT of the abdomen with a bone scan is an acceptable, less sensitive substitute. If treatment is delayed by 8 weeks or more, or new symptoms appear, re-image before starting. Confirm PET-positive mediastinal nodes with EBUS before ruling out surgery: false positives from granulomas are frequent in India.
- **Brain MRI with contrast** for all clinical stage III–IV NSCLC (NCCN extends this to stage II), all small cell lung cancer, and anyone with neurological symptoms. Contrast CT of the brain is a poorer substitute when MRI is not possible.
- **Invasive mediastinal staging** (EBUS ± EUS, then mediastinoscopy or surgical nodal dissection if EBUS is negative but suspicion remains) for central tumours, tumours over 3 cm, N1 on imaging or PET-positive mediastinum. Small (up to about 3 cm) peripheral tumours with no suspicious nodes can go straight to surgery with systematic nodal dissection. Bulky tumour infiltrating the mediastinum is staged on imaging; the biopsy only needs to confirm the diagnosis.

- **Pleural effusion**: a malignant effusion is M1a. Send at least 50 mL, ideally under ultrasound guidance; one cytology sample finds cancer in only about half to nine-tenths of cases, and a second or third sample adds yield. Thoracoscopic biopsy is the most sensitive (80–99%). Blind closed pleural biopsy, common for TB in India, has limited value for cancer.
- **Fitness for surgery** (ACCP approach): FEV_1 and DLCO in everyone, then the predicted post-operative (ppo) value = measured value × (1 - segments removed ÷ functioning segments; 19 in total). Both ppo values ≥60% → low risk, no further tests. Either 30–60% → stair climb (≥22 m) or shuttle walk (≥400 m); pass → proceed, fail → cardiopulmonary exercise test. Either below 30% → exercise test directly. VO_2 max above 20 mL/kg/min is low risk, 10–20 individualise, below 10 points to sublobar surgery or SBRT. **Repeat lung function after any induction therapy**, because chemo-immunotherapy and radiotherapy lower DLCO.
- **More than one lung lesion**: decide in the tumour board whether they are separate primaries or intrapulmonary metastases (histology, imaging pattern, molecular comparison). Multifocal ground-glass adenocarcinoma is its own entity: treat each lesion with curative intent, with lung-sparing resection or SBRT, and base adjuvant therapy on the highest-stage lesion.
- Stage with the **IASLC/UICC 9th edition** (in force from January 2025; Figure 6). Small cell lung cancer has its own mini review.

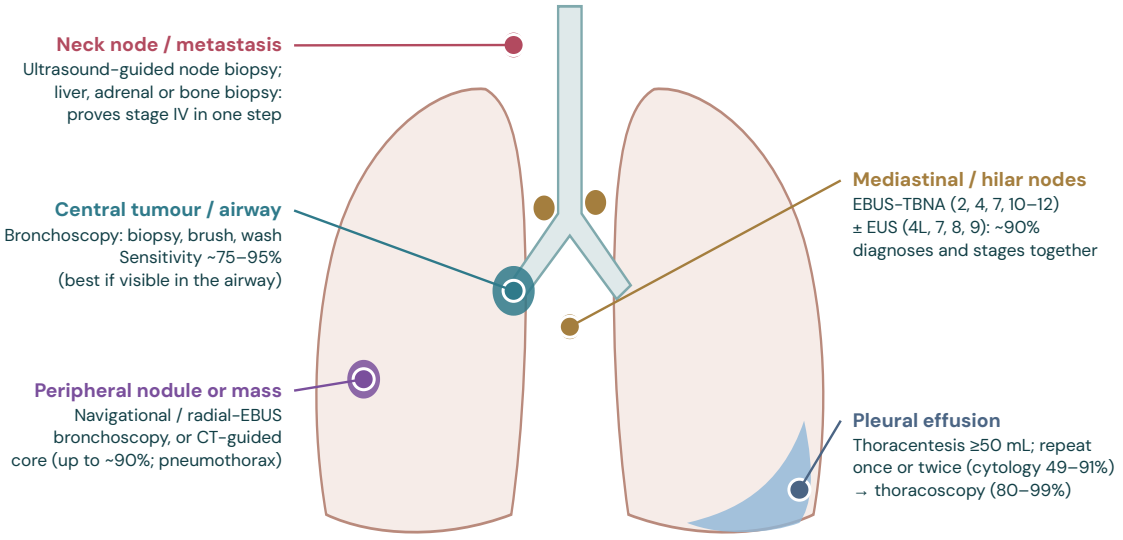

Rule: biopsy the site that proves the HIGHEST stage, with the least risk, and get enough tissue (core or cell block) for NGS and PD-L1.
Sputum cytology only for central tumours when nothing else is possible; it never stages.

Figure 5. Which biopsy, for which lesion. One well-chosen procedure should give the diagnosis, the stage and enough tissue for biomarkers.

	Healed TB / fungal granuloma	Lung cancer
	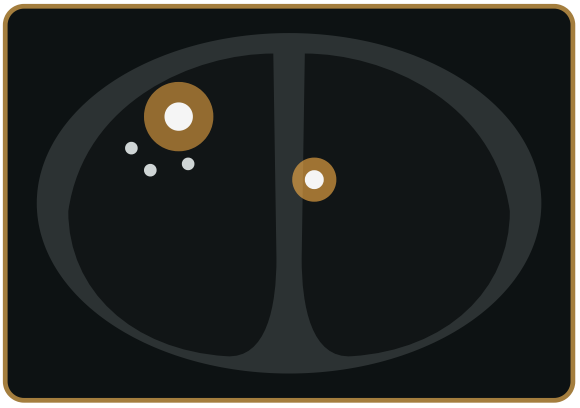	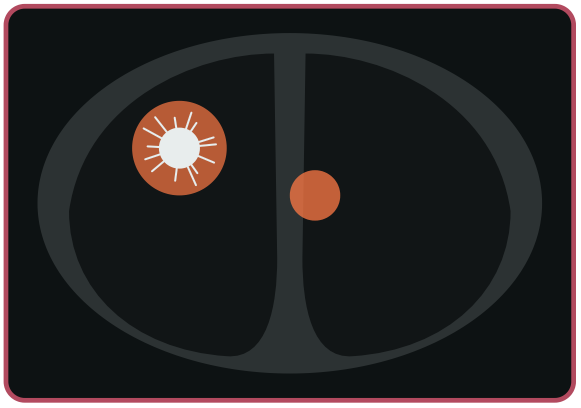
Nodule	Smooth, often calcified; satellite nodules, scarring, upper-lobe fibrosis	Irregular or spiculated; grows on serial CT
Nodes	Calcified, symmetrical, long history	Enlarging, asymmetrical, necrotic
PET uptake	Can be HIGH (active granulomas)	Usually high; low in some adenocarcinomas
Next step	Tissue / EBUS (+ TB tests) before calling it cancer	Tissue / EBUS before treatment

Both can light up on PET. In India, never deny surgery or start cancer treatment on PET alone: prove it with tissue.

Figure 6. The PET trap in India (schematic; orange = PET uptake). Granulomas from TB or fungal infection can be as PET-avid as cancer, so mediastinal nodes and nodules need tissue confirmation.

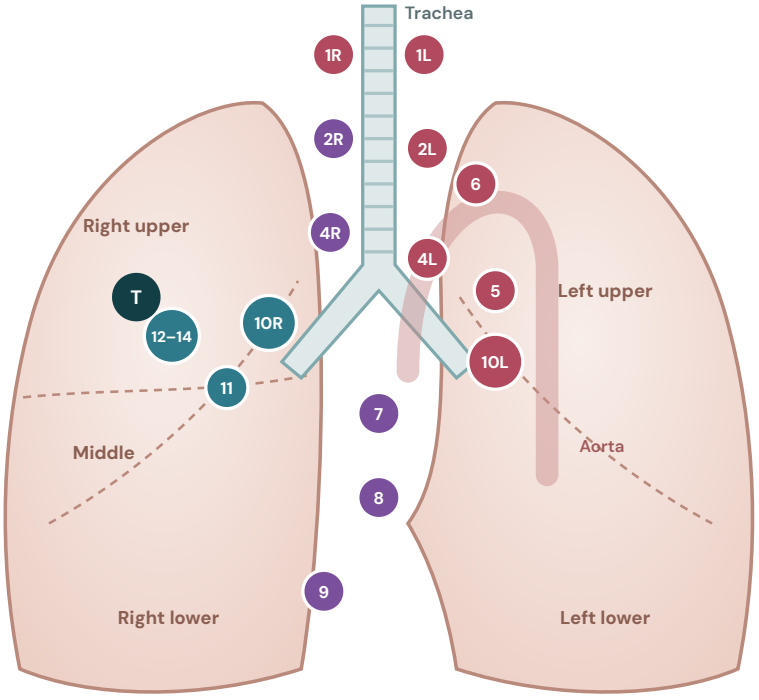

For a RIGHT-sided tumour

- **N1** Hilar, interlobar, lobar (10–14), same side
- **N2** Same-side mediastinal or subcarinal (2R, 4R, 7–9)
- **N3** Opposite-side nodes, or any scalene or supraclavicular node (1)

9th edition: N2a = one N2 station; N2b = more than one N2 station.

Reach of each test

- EBUS-TBNA: 2, 3p, 4, 7, 10–12
- EUS (oesophageal): 4L, 7, 8, 9 + adrenal
- Mediastinoscopy: 2, 4, 7
- VATS or anterior approach: 5, 6

Left-sided tumour: 2L, 4L, 5, 6 become N2 right-sided stations become N3.

Figure 7. Lobes and lymph-node stations (IASLC map, simplified front view; the patient's right lung is on the left). The N category depends on the side of the tumour, which is why every node station is named in reports and EBUS samples.

T: primary tumour (circles to scale)

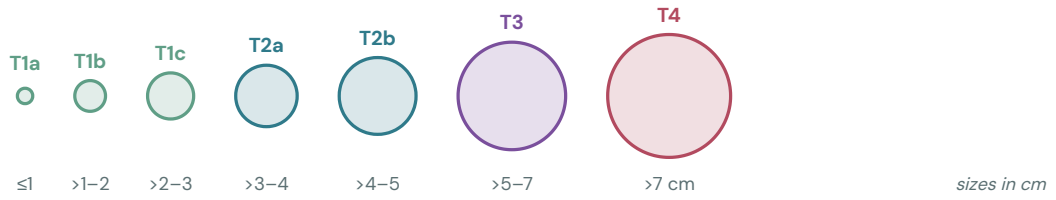

Invasion upgrades T regardless of size

- **T2** Main bronchus (not carina), visceral pleura, atelectasis to the hilum
- **T3** Chest wall, parietal pleura or pericardium, phrenic nerve; separate nodule in the same lobe
- **T4** Mediastinum, heart, great vessels, trachea, carina, oesophagus, vertebra, diaphragm, recurrent laryngeal nerve; separate nodule in a different lobe on the same side

N and M (9th edition changes in bold)

- **N1** Ipsilateral hilar / intrapulmonary nodes
- **N2a** **One ipsilateral mediastinal or subcarinal station**
- **N2b** **Two or more N2 stations**
- **N3** Contralateral mediastinal/hilar, or scalene/supraclavicular
- **M1a** Other-lung nodule; pleural/pericardial spread or effusion
- **M1b** Single extrathoracic metastasis
- **M1c1** **Multiple metastases in one organ system**
- **M1c2** **Metastases in several organ systems**

Stage groups (simplified)

IA	IB	IIA	IIB	IIIA	IIIB	IIIC	IVA	IVB
T1 N0	T2a N0	T2b N0	T1–2 N1 T3 N0 T1 N2a	T1 N2b T2 N2a T3 N1 T4 N0–1	T2 N2b T3–4 N2 T1–2 N3	T3–4 N3	M1a, M1b	M1c

IASLC/UICC 9th edition (from 2025). T categories are unchanged from the 8th; N2 and M1c are now subdivided. Check the full table before a final st

Figure 8. TNM at a glance (IASLC/UICC 9th edition, simplified). Small differences in T, N2a versus N2b, or one versus several metastatic sites change both stage and treatment intent.

04 Biomarkers that change treatment

- **Who to test**: every advanced or recurrent non-squamous NSCLC; squamous NSCLC in never- or light smokers, young patients or mixed histology; and, for early-stage decisions, *EGFR* and *ALK* (with PD-L1) in all resected or resectable stage IB–III NSCLC.
- **How**: a next-generation sequencing panel covering DNA and RNA (fusions) is preferred. Single-gene *EGFR* PCR plus *ALK* IHC (D5F3) is acceptable where NGS is unaffordable, but misses *ROS1*, *RET*, *MET* exon 14, *BRAF*, *KRAS* G12C, *HER2* and uncommon *EGFR* variants.
- **Plasma ctDNA** when tissue is scant or slow: a positive result can be acted on; a negative result does not exclude a driver, so test tissue as well.
- ***EGFR* exon 19 deletion or L858R** → osimertinib-based first-line therapy; adjuvant osimertinib after resection; osimertinib after chemoradiation. Uncommon *EGFR* variants (G719X, L861Q, S768I) → afatinib or osimertinib. Exon 20 insertions → amivantamab with chemotherapy.
- ***ALK* fusion** → alectinib, lorlatinib or brigatinib; adjuvant alectinib after resection. ***ROS1*** → taletrectinib (**TRUST**[5]) or repotrectinib preferred, entrectinib acceptable, crizotinib less preferred (it misses the brain); zidesamtinib after progression. ***RET*** → selpercatinib, also as adjuvant therapy after resection (**LIBRETTO-432**[6]).
- ***BRAF* V600E** → dabrafenib + trametinib or encorafenib + binimetinib; ***MET* exon 14** → capmatinib or tepotinib; ***NTRK*** → a TRK inhibitor or chemo-immunotherapy (both reasonable first). ***KRAS* G12C** → chemo-immunotherapy first, then sotorasib or adagrasib. ***HER2* (*ERBB2*) mutation** → the oral HER2 inhibitor zongertinib (**Beamion LUNG-1**[7]) or trastuzumab deruxtecan, usually after chemo-immunotherapy.
- **Protein and rarer targets**: HER2 overexpression (IHC 3+) → trastuzumab deruxtecan after first line; high c-MET protein overexpression (strong 3+ staining in ≥50% of cells, non-squamous) → telisotuzumab vedotin after first line where approved; *NRG1* fusion (found by RNA NGS) → zenocutuzumab, usually after chemo-immunotherapy. Ask the pathologist for these stains when tissue allows.
- **PD-L1 tumour proportion score** (22C3 or a validated equivalent) → choice between immunotherapy alone and chemo-immunotherapy in driver-negative disease (Figure 10). Tumour mutational burden is not used routinely. *STK11* or *KEAP1* co-mutations predict poorer immunotherapy benefit but are not a reason to withhold it.
- **At progression on a TKI**: re-biopsy or ctDNA. Look for *MET* amplification, new *EGFR* or *ALK* resistance mutations (for example *ALK* G1202R, which responds to lorlatinib) and small-cell transformation.

Approximate frequency in Indian lung adenocarcinoma (varies by series, smoking and test)

		First-line matched option (no doses)
EGFR (exon 19 del / L858R)	~28%	osimertinib ± chemo · amivantamab-lazertinib
EGFR uncommon / exon 20 ins	~3%	afatinib or osimertinib · amivantamab + chemo (ex20)
ALK fusion	~5%	alectinib · lorlatinib · brigatinib
ROS1 fusion	~2%	taletrectinib · repotrectinib · entrectinib
KRAS (G12C ~ 1 in 3 of KRAS)	~7%	chemo-immunotherapy first; sotorasib / adagrasib later
BRAF V600E	~1.5%	dabrafenib + trametinib · encorafenib + binimetinib
MET exon 14 skipping	~2%	capmatinib · tepotinib
RET fusion	~1.5%	selpercatinib · pralsetinib
HER2 (ERBB2) mutation	~2%	zongertinib or trastuzumab deruxtecan (usually after chemo-I(
NTRK fusion	<1%	larotrectinib · entrectinib, or chemo-IO
No driver found	~47%	PD-L1-guided immunotherapy ± chemotherapy

Test every non-squamous NSCLC, and squamous NSCLC in never- or light smokers. Gefitinib + chemotherapy is a proven, cheaper EGFR option. EGFR PCR alone misses fusions, exon 20 insertions and other targets: use NGS with RNA where possible.

Figure 9. The driver map. About half of Indian adenocarcinomas carry an actionable alteration; most of these patients do better with a matched oral drug than with immunotherapy.

EGFR kinase domain: where the mutations sit and what they mean

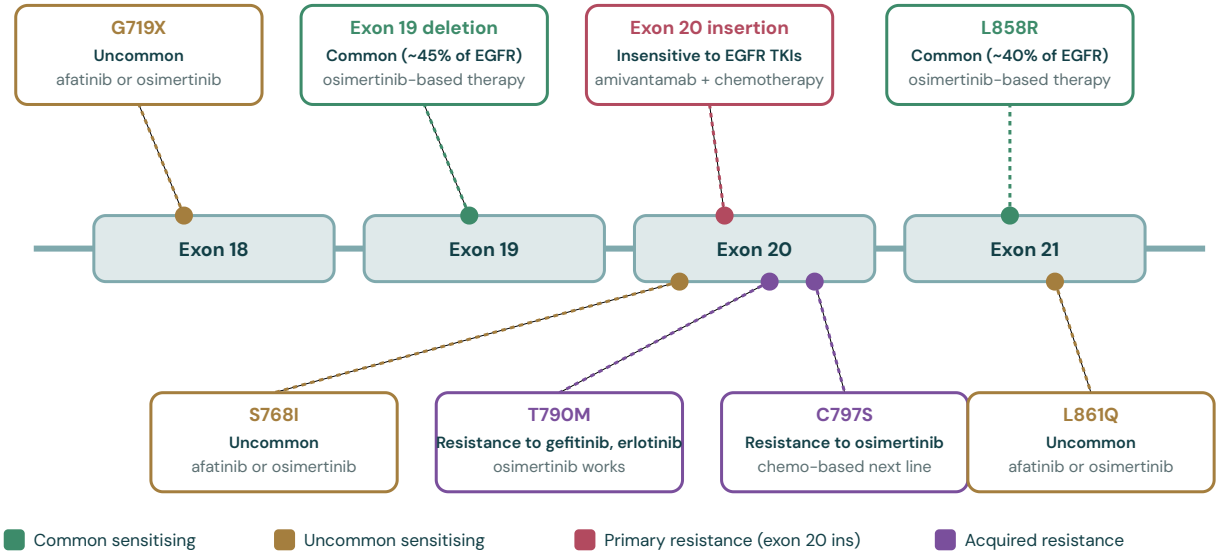

Also at osimertinib progression: MET or HER2 amplification and small-cell transformation (re-biopsy). Plasma ctDNA can find many of these.

Figure 10. The EGFR mutation map. Knowing which exon is involved predicts which drug will work, and which will not.

05 Local therapy: surgery & radiotherapy

Surgery: types, pros and cons

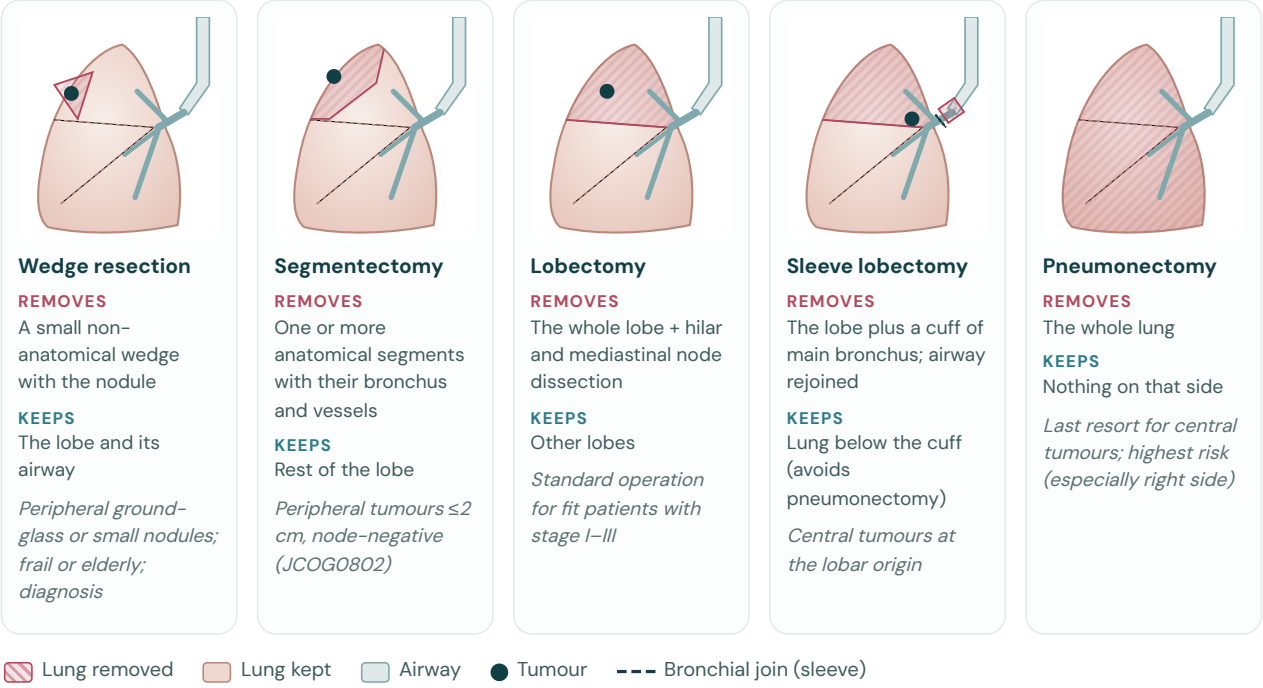

Figure 11. Types of lung resection (schematic right lung, front view; dashed lines are the fissures). Every resection includes systematic sampling or dissection of hilar and mediastinal nodes; lung-sparing operations are preferred whenever they are oncologically adequate.

Procedure	Best suited to	Advantages	Disadvantages
Lobectomy + systematic nodal dissection (VATS or robotic where available)	Fit patients with stage I–II, and selected stage III after neoadjuvant therapy	Standard of care; lowest local recurrence for larger or central tumours	Loses a whole lobe of function; needs adequate lung reserve
Segmentectomy (anatomical)	Peripheral (outer third) tumours ≤2 cm with a consolidation-to-tumour ratio above 0.5, lobar nodes negative on frozen section	Spares lung; overall survival as good or better than lobectomy (JCOG0802[8])	Local recurrence roughly doubled in JCOG0802; technically demanding; needs negative nodes
Wedge resection	Small peripheral or ground-glass-predominant nodules; frail patients; diagnosis	Quick, minimal lung loss; sublobar resection non-inferior in CALGB 140503[9] (mostly wedges) for ≤2 cm N0	Narrow margins; limited nodal sampling unless added deliberately
Sleeve lobectomy	Central tumours at a lobar bronchus origin	Avoids pneumonectomy, with better function and survival	Anastomotic complications; specialist surgery
Pneumonectomy	Central tumours that cannot be removed otherwise	Complete resection when no alternative	Highest operative mortality (especially right-sided, after induction therapy); lifelong reduced reserve

- **Lymph nodes**: sample or dissect at least three mediastinal stations (always including the subcarinal, station 7) and the hilar nodes. Unsampled nodes mean an incomplete stage.
- **Margins**: aim for R0. A positive bronchial margin (R1) needs re-resection or postoperative radiotherapy.
- **N2 disease**: most clinical N2 is treated with definitive chemoradiation. Surgery after induction (chemo-immunotherapy or chemoradiation) suits selected patients: single-station N2 under 3 cm before treatment, resectable by lobectomy, and responding to induction. Against surgery: poor performance status, progression on induction, extracapsular spread, T4 tumours, multi-station N2. Decide in a tumour board.
- **Pancoast tumours**: induction chemoradiation followed by surgery when resectable.
- **Oligometastatic disease** (usually 1–3, at most 5, metastases in few organs, good performance status): give at least about 3 months of systemic therapy first so that hidden widespread disease can declare itself, then treat every site with surgery or ablative radiotherapy (randomised phase 2 data: **Gomez et al.**[10], **SABR-COMET**[11]). For oligoprogression on a TKI, pause the drug around local treatment.

Radiotherapy: when, how, and how long

- **SBRT (stereotactic ablative radiotherapy)** for stage I NSCLC in patients who are medically inoperable or decline surgery: local control around 90% in 3–8 sessions. Central and ultra-central tumours need more fractions and caution. Get tissue first whenever safely possible; in India granulomas can mimic cancer on PET.
- **Definitive chemoradiation** for unresectable stage III: about 60 Gy in 30 daily sessions with concurrent platinum chemotherapy. Concurrent is better than sequential (around a 4–5% absolute 5-year survival gain) but more toxic; sequential suits frailer patients. Dose escalation to 74 Gy was harmful (RTOG 0617). IMRT lowers lung and heart dose. Common concurrent partners: cisplatin–etoposide, weekly carboplatin–paclitaxel, or platinum–pemetrexed (non-squamous). Patients too frail for combined treatment: radiotherapy with single-agent sensitising chemotherapy, or sequential treatment. Then consolidation: durvalumab (**PACIFIC**[12]) or, for *EGFR*-mutant tumours, osimertinib (**LAURA**[13]).
- **Postoperative radiotherapy** is not routine after complete resection of pN2 disease: **Lung ART**[14] showed no disease-free survival gain and more cardiopulmonary deaths. Use it for positive margins; some centres still offer it for the highest-risk N2 (multi-station, extracapsular spread, inadequate nodal sampling). Never after complete resection of stage I–II.
- **Palliative radiotherapy** for haemoptysis, bone pain, airway obstruction, SVC obstruction (with stenting for rapid relief) and cord compression: one, five or ten sessions.
- **Brain metastases** (about one in ten at diagnosis of advanced NSCLC): severe mass effect → neurosurgery first. Otherwise the driver decides: *EGFR*, *ALK*, *RET* or *ROS1* (with a brain-penetrant inhibitor) → start the TKI and repeat MRI at 6–8 weeks; *MET* exon 14, *KRAS* G12C or *BRAF* → radiotherapy, then systemic therapy; no driver → radiotherapy (radiosurgery for a limited number, hippocampal-avoidance whole-brain radiotherapy with memantine for many), or systemic therapy first if asymptomatic.

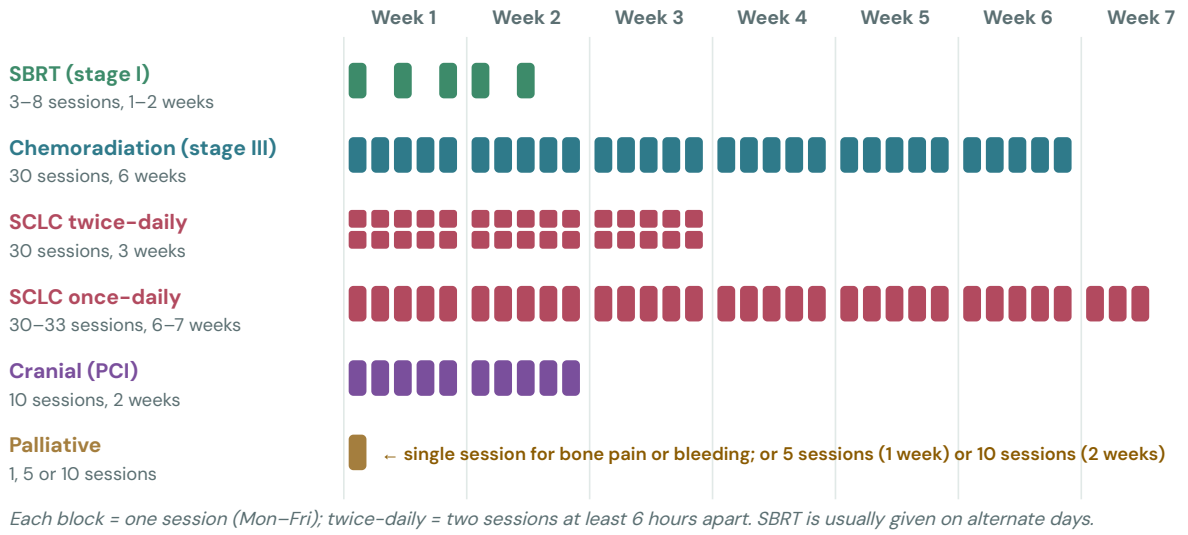

Figure 12. Radiotherapy schedules at a glance. SBRT gives a curative dose in a handful of sessions; chemoradiation needs six weeks of daily attendance, which must be planned with the family.

Interstitial lung disease (ILD): a special situation

- Patients with ILD (including IPF) have a much higher lung cancer risk and a much higher risk from every treatment: acute exacerbation after surgery, severe radiation pneumonitis, and drug or immune pneumonitis.
- Stage I–II NSCLC with adequate lung function: surgery first, favouring sublobar (lung-sparing) resection; SBRT is not clearly safer. Small cell T1–2 NO: surgery is also preferred.
- Patients with ILD were excluded from the perioperative immunotherapy trials. Discuss checkpoint inhibitors case by case with an ILD-experienced pulmonologist; chemoradiation is possible but riskier.
- Weigh the cancer's threat against the expected course of the ILD itself, and use a nodule risk tool (for example the Brock calculator) before deciding how hard to chase a tissue diagnosis.

06 Systemic therapy: indications & options

Indications and options only; no doses. Benefits are given in absolute terms where possible. Trial names link to the primary publications.

Early and locally advanced NSCLC

Setting	Options	Evidence and size of benefit
Stage IA after resection	None (surveillance)	Adjuvant chemotherapy does not help and may harm.
Resected IB (≥4 cm or high-risk: lymphovascular invasion, high grade, very PET-avid) to IIIA, no driver	Cisplatin-based doublet × 4 (cisplatin–pemetrexed if non-squamous; carboplatin only if cisplatin-unfit); then atezolizumab (≥5 cm or N+, PD-L1 ≥1%) or pembrolizumab (≥4 cm or N+). Adjuvant immunotherapy only if chemotherapy was given	LACE[15]: about 5% absolute 5-year survival gain from chemotherapy. IMpower010[16] and PEARLS/KEYNOTE-091[17]: disease-free survival gain; atezolizumab benefit concentrated in PD-L1 ≥50%.
Resected IB–IIIA, *EGFR* ex19del/L858R	Chemotherapy if indicated, then osimertinib for 3 years	ADAURA[18]: disease-free survival hazard ratio about 0.2; ADAURA OS[19]: 5-year overall survival 88% vs 78%.
Resected IB–IIIA, *ALK*+	Alectinib for 2 years (instead of chemotherapy)	ALINA[20]: 2-year disease-free survival 94% vs 63%; overall survival data immature.
Resectable stage II, and stage III (N0–1 or selected single-station N2), no driver	Preferred: neoadjuvant platinum doublet + nivolumab, pembrolizumab or durvalumab (3–4 cycles), surgery, then the same antibody for up to a year (perioperative). Surgery first, then adjuvant therapy, remains acceptable	CheckMate 816[21] (neoadjuvant only) and perioperative KEYNOTE-671[22], AEGEAN[23], CheckMate 77T[24]: pathological complete response about 17–25% vs 2–4%; event-free survival HR about 0.6. KEYNOTE-671 has shown a significant overall survival gain.
Resectable stage II–III, *EGFR*+, *ALK*+ or *RET*+	Usually surgery first, then adjuvant osimertinib (3 years, after chemotherapy), alectinib (2 years) or selpercatinib (up to 3 years). If induction is needed: osimertinib ± chemotherapy for *EGFR* (NeoADAURA[25]); chemotherapy alone for *ALK*	Neoadjuvant immunotherapy is not used for these tumours. LIBRETTO-432[6]: 2-year event-free survival 94% vs 70% with adjuvant selpercatinib (small trial, short follow-up).
Unresectable stage III, no driver	Concurrent chemoradiation, then durvalumab for 12 months	PACIFIC[12]: 5-year survival 43% vs 33% (5-year update[26]). Start within 6 weeks of radiotherapy.
Unresectable stage III, *EGFR*+	Chemoradiation, then osimertinib until progression	LAURA[13]: median progression-free survival 39 vs 6 months; overall survival immature. Do not give durvalumab to *EGFR*- or *ALK*-positive tumours.

Metastatic NSCLC with a driver

Driver	First line	Notes
EGFR ex19del / L858R	Osimertinib; osimertinib + platinum–pemetrexed; amivantamab + lazertinib. Where osimertinib is unaffordable: gefitinib + pemetrexed–carboplatin	**FLAURA**[27]: osimertinib beat gefitinib/erlotinib including overall survival (**OS 38.6 vs 31.8 months**[28]). **FLAURA2**[29]: adding chemotherapy improved progression-free and now overall survival (**median 47.5 vs 37.6 months**[30]), with more toxicity. **MARIPOSA**[31]: amivantamab–lazertinib beat osimertinib (PFS 23.7 vs 16.6 months; overall survival also favoured it), with skin toxicity and clots (give anticoagulant prophylaxis). The **Tata Memorial trial**[32] showed gefitinib + chemotherapy beats gefitinib alone for survival: an affordable Indian standard.
EGFR exon 20 insertion	Amivantamab + carboplatin–pemetrexed	**PAPILLON**[33]. Earlier EGFR TKIs do not work.
ALK	Alectinib, lorlatinib or brigatinib	**ALEX**[34]; **CROWN**[35]: lorlatinib gave the longest progression-free survival seen in lung cancer (about 60% progression-free at 5 years) and strong brain control, at the cost of weight gain, lipids and mood or cognitive effects. Crizotinib is inferior.
ROS1, *BRAF* V600E, *MET* ex14, *RET*, *NTRK*	Matched TKI (Figure 7): taletrectinib or repotrectinib for *ROS1*; selpercatinib for *RET*; for *NTRK*, a TRK inhibitor or chemo-immunotherapy	**LIBRETTO-431**[36]: selpercatinib beat chemotherapy ± pembrolizumab for *RET*. If a result is pending and the patient is unwell, chemotherapy without immunotherapy is a safe bridge.
KRAS G12C; *HER2* mutation; *NRG1* fusion	Chemo-immunotherapy first (zongertinib can be used earlier for *HER2* where approved)	Next line: sotorasib or adagrasib (**CodeBreaK 200**[37]: modest progression-free gain, no survival gain); zongertinib (**Beamion LUNG-1**[7]) or trastuzumab deruxtecan (**DESTINY-Lung01**[38]; watch for pneumonitis) for *HER2*; zenocutuzumab for *NRG1*.
Progression on osimertinib	Re-biopsy or ctDNA; platinum–pemetrexed ± amivantamab; continue osimertinib for isolated brain or oligoprogression with local therapy	Immunotherapy alone is ineffective after EGFR-TKI failure. Small-cell transformation → platinum–etoposide.

Metastatic NSCLC without a driver

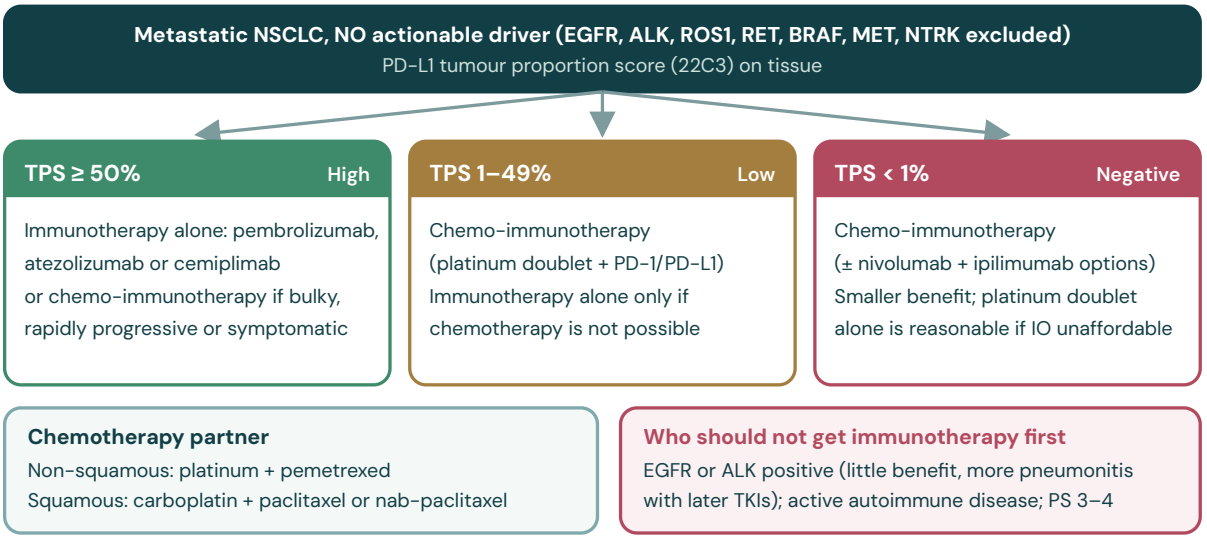

Figure 13. PD-L1 guides, but does not dictate. Response rates rise with PD-L1, yet some PD-L1-negative tumours respond and some high expressers do not; performance status and disease tempo matter as much.

- **PD-L1 ≥50%**: pembrolizumab alone (KEYNOTE-024[39]: 5-year survival about 32% vs 16% in the 5-year update[40]), atezolizumab or cemiplimab; chemo-immunotherapy when disease is bulky or rapid.
- **PD-L1 1–49% and <1%**: platinum doublet (carboplatin usually preferred over cisplatin) plus pembrolizumab (KEYNOTE-189[41] non-squamous, KEYNOTE-407[42] squamous). Immunotherapy alone at 1–49% is weak: in KEYNOTE-042[43] the overall benefit was driven by the ≥50% subgroup, a lesson in reading subgroups. For PD-L1-negative tumours, regimens adding CTLA-4 blockade (nivolumab + ipilimumab, or durvalumab + tremelimumab, usually with chemotherapy) appear more effective than a single checkpoint inhibitor.
- **How long**: four cycles of platinum is standard; continue the antibody (pembrolizumab can be given 6-weekly) for about 2 years, then decide with the patient whether to stop or continue.
- **Maintenance**: pemetrexed (non-squamous) with the antibody. **Bevacizumab** only in non-squamous tumours without haemoptysis or central cavitation.
- **Progression after immunotherapy alone**: a platinum doublet. Rechallenge with immunotherapy can work when progression comes 6 months or more after stopping it; oligoprogression can be treated locally while continuing the antibody.
- **Progression after chemo-immunotherapy**: pemetrexed if not yet used (non-squamous), otherwise docetaxel, with ramucirumab for fit patients (REVEL[44]: median survival 10.5 vs 9.1 months), or gemcitabine. Adding immunotherapy again is not standard outside trials. Re-test for HER2 or c-MET overexpression, which open targeted options.
- **Relapse after curative treatment** (adjuvant therapy or chemoradiation): more than 12 months later → treat as first-line metastatic disease; within 6 months → second-line therapy; 6–12 months → individualise by burden, tempo and previous response.
- **Performance status 2 or elderly**: single-agent chemotherapy, carboplatin doublet or immunotherapy alone if PD-L1 is high. **PS 3–4**: best supportive care, except with a driver, where a TKI can restore function within weeks.
- **Early palliative care** alongside treatment improves quality of life and mood, and in the Temel trial[45] was associated with longer survival.
- **Bone metastases**: zoledronic acid or denosumab with calcium and vitamin D; dental review first.
- **Toxicities to know**: immune pneumonitis, colitis, hepatitis, thyroid and adrenal failure (check TSH, cortisol); EGFR-TKI rash, paronychia and rare interstitial lung disease; alectinib CPK and bilirubin rises; lorlatinib lipids, oedema and mood change; amivantamab infusion reactions, rash and thromboembolism.
- **Drug-induced pneumonitis** (TKIs, antibody–drug conjugates such as trastuzumab deruxtecan, immunotherapy) is a diagnosis of exclusion: rule out infection (including TB), radiation injury and progression. Hold the drug for any suspected significant pneumonitis, stop permanently for severe (grade 4) toxicity, and give a short course of high-dose steroids for severe or progressive cases. Anti-VEGF drugs add haemorrhage, cavitation and pneumothorax risks.
- **Pre-existing ILD or autoimmune disease**: higher risk of severe pneumonitis; decide on immunotherapy case by case with the relevant specialist.
- **Sequence matters**: immunotherapy shortly before osimertinib raises the risk of severe pneumonitis. Wait for EGFR/ALK results whenever the clinical state allows.

SHARE WITH PATIENTS: TREATMENT QUESTIONS

Plain-language myth pages written for patients and families. Send them from the clinic to reinforce what you discussed.

Tablets for lung cancer are weaker than 'real' chemotherapy?

Immunotherapy and targeted therapy have no side effects?

Herbal or traditional medicine can cure lung cancer instead of medical treatment?

All lung cancers are the same and get the same treatment?

Every patient with lung cancer must have chemotherapy?

Surgery is the only way to cure lung cancer?

Radiotherapy always destroys the entire lung?

If lung cancer has spread to the lymph nodes, it is automatically stage IV?

Stage IV lung cancer means treatment is useless?

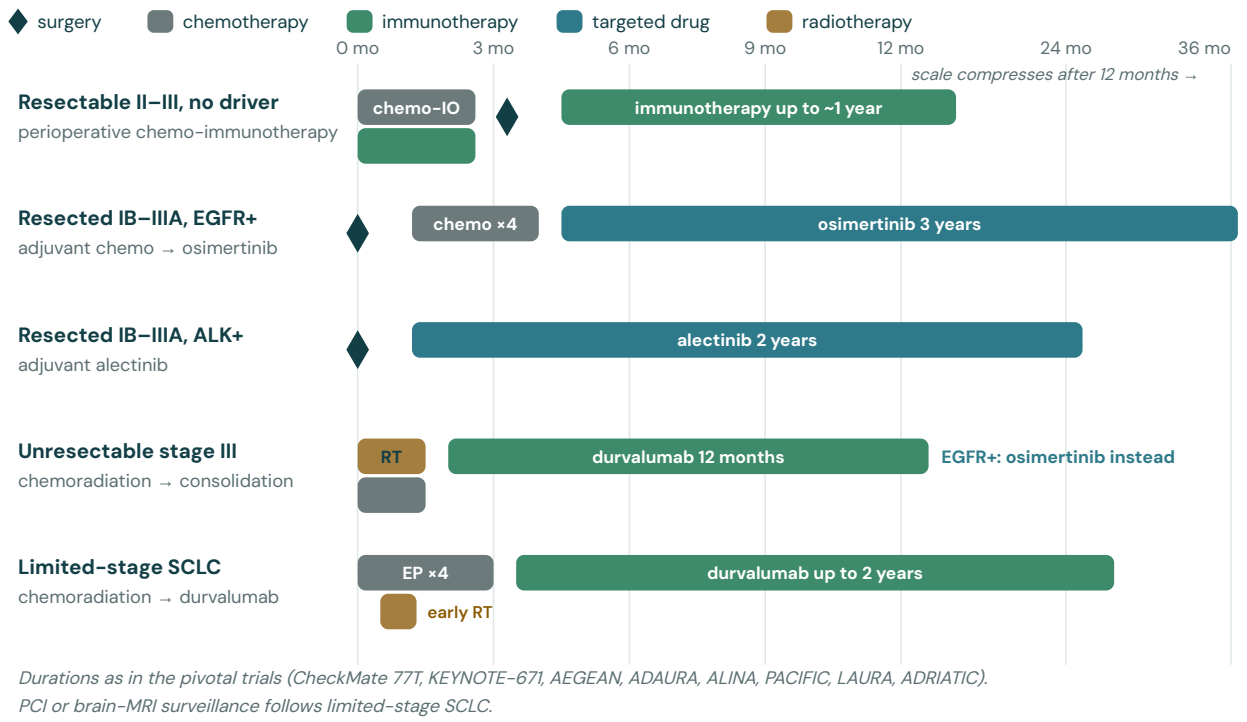

Figure 14. Treatment calendars for curative-intent settings. Plan the whole year at the start: visits, scans, cost and the family's commitment.

Quick-reference tables: targeted therapy, immunotherapy and side effects

For orientation only; no doses. Check current approvals and product information in India.

Table A. Actionable alterations and targeted therapy

Alteration (how to find it)	Preferred first line	Alternatives and later lines	Key evidence	Brain activity	Signature side effects · what to monitor
***EGFR* exon 19 del / L858R** ~25–35% of Indian adenocarcinoma · PCR or NGS · plasma OK	Osimertinib; osimertinib + platinum–pemetrexed; amivantamab + lazertinib	Gefitinib + pemetrexed–carboplatin (affordable); gefitinib, erlotinib, afatinib. After osimertinib: chemo ± amivantamab; re-biopsy for MET, C797S, SCLC transformation	FLAURA[27], FLAURA2[29], MARIPOSA[31], Tata Memorial[32]	High (osimertinib, combinations)	Osimertinib: rash, paronychia, diarrhoea, dry skin, QTc prolongation, rare ILD and fall in LVEF · ECG, echo if cardiac risk. Amivantamab: infusion reactions, acneiform rash, paronychia, oedema, low albumin, venous thrombosis (prophylactic anticoagulation early)
***EGFR* uncommon (G719X, L861Q, S768I)**	Afatinib or osimertinib	Chemo-immunotherapy at progression is of limited benefit	Pooled phase 2 and subgroup data	Moderate (osimertinib)	Afatinib: diarrhoea (often severe early), rash, stomatitis, paronychia
***EGFR* exon 20 insertion** missed by many PCR kits · use NGS	Amivantamab + carboplatin–pemetrexed	Platinum-based chemotherapy; trials	PAPILLON[33]	Limited	Infusion reactions (first dose), rash, paronychia, neutropenia, oedema, hypoalbuminaemia
***ALK* fusion** ~5% · IHC (D5F3) or NGS/FISH	Alectinib, lorlatinib or brigatinib	After alectinib/brigatinib: lorlatinib (re-biopsy for G1202R); then chemotherapy (pemetrexed-based)	ALEX[34], CROWN[35]; adjuvant ALINA[20]	High (lorlatinib highest)	Alectinib: myalgia, raised CPK and bilirubin, oedema, weight gain, constipation, photosensitivity, bradycardia. Lorlatinib: high cholesterol and triglycerides, weight gain, oedema, neuropathy, mood, sleep and cognitive change · lipids, mood. Brigatinib: early pulmonary events in the first week (step-up start), hypertension, CPK, lipase
***ROS1* fusion** 1–2% · NGS (RNA) or IHC screen	Taletrectinib or repotrectinib (entrectinib acceptable; crizotinib less preferred)	Zidesamtinib after progression; chemotherapy	TRUST[5]	High except crizotinib	Taletrectinib: raised liver enzymes, nausea, diarrhoea, QTc. Repotrectinib and entrectinib: dizziness, taste change, paraesthesia, ataxia, weight gain (TRK effects). Crizotinib: visual trails, oedema, nausea, liver enzymes, bradycardia
***BRAF* V600E** ~1–2% · NGS or PCR	Dabrafenib + trametinib, or encorafenib + binimetinib	Chemo-immunotherapy (these tumours can respond to immunotherapy)	Phase 2 trials	Moderate	Dabrafenib + trametinib: fever (hold both until settled), rash, fatigue, fall in LVEF, serous retinopathy. Encorafenib + binimetinib: nausea, diarrhoea, fatigue, CPK rise, retinal effects · echo, eye review if visual change

Alteration (how to find it)	Preferred first line	Alternatives and later lines	Key evidence	Brain activity	Signature side effects · what to monitor
***MET* exon 14 skipping** ~2–3%, older patients · RNA NGS best	Capmatinib or tepotinib	Chemo-immunotherapy; crizotinib	Phase 2 trials	Moderate	Peripheral oedema (very common, slow to settle), nausea, low albumin, apparent creatinine rise (transporter effect, not true kidney injury), rare ILD, photosensitivity (capmatinib)
c-MET protein overexpression IHC 3+ in ≥50% of cells, non-squamous, after first line	Telisotuzumab vedotin (where approved)	Docetaxel-based therapy	Phase 2 data	Unknown	Peripheral neuropathy, oedema, fatigue, ILD (antibody–drug conjugate)
***RET* fusion** 1–2% · RNA NGS	Selpercatinib (pralsetinib alternative)	Adjuvant selpercatinib after resection; chemotherapy at progression	LIBRETTO-431[36]; adjuvant LIBRETTO-432[6]	High	Selpercatinib: hypertension, raised liver enzymes, QTc, dry mouth, diarrhoea, oedema, hypersensitivity, chylous effusions. Pralsetinib: cytopenias, hypertension, pneumonitis, infections · BP, LFT, ECG
***NTRK* 1–3 fusion** <1% · RNA NGS	Larotrectinib or entrectinib, or chemo-immunotherapy	Repotrectinib for resistance	Basket trials	High	Dizziness, weight gain, paraesthesia, liver enzymes; pain on stopping the drug (TRK withdrawal)
***KRAS* G12C** ~1 in 3 KRAS mutations, smokers	Chemo-immunotherapy first	Sotorasib or adagrasib after progression	CodeBreaK 200[37]	Some (adagrasib)	Sotorasib: diarrhoea, nausea, hepatotoxicity (higher if started soon after immunotherapy). Adagrasib: nausea, vomiting, diarrhoea, QTc, liver enzymes
***HER2* (*ERBB2*) mutation** ~2–3% · NGS	Chemo-immunotherapy, or zongertinib where approved	Zongertinib or trastuzumab deruxtecan after first line	Beamion LUNG-1[7], DESTINY-Lung01[38]	Moderate	Trastuzumab deruxtecan: ILD/pneumonitis (about 1 in 10; stop for any grade 2+), nausea, hair loss, neutropenia, fall in LVEF. Zongertinib: diarrhoea, rash, liver enzymes
***NRG1* fusion** rare · RNA NGS	Chemo ± immunotherapy (zenocutuzumab in selected patients)	Zenocutuzumab after first line	Phase 2 data	Unknown	Diarrhoea, infusion reactions, fatigue; check LVEF

Table B. When to use immunotherapy

Setting	Who	Immunotherapy used	Key evidence	Do not use, or use with caution
Metastatic NSCLC, no driver, PD-L1 ≥50%	PS 0–1 (PS 2 selected)	Pembrolizumab, atezolizumab or cemiplimab alone; chemo-immunotherapy if bulky or rapidly progressive	KEYNOTE-024[39], 5-year update[40]	Any actionable driver (EGFR, ALK, ROS1, RET): targeted therapy first
Metastatic NSCLC, no driver, PD-L1 1–49%	PS 0–1	Platinum doublet + pembrolizumab (or other PD-(L)1 antibody); immunotherapy alone only if chemotherapy is impossible	KEYNOTE-189[41], KEYNOTE-407[42], KEYNOTE-042[43]	Squamous: no pemetrexed
Metastatic NSCLC, no driver, PD-L1 <1%	PS 0–1	Chemo-immunotherapy; regimens adding CTLA-4 blockade (nivolumab + ipilimumab ± chemo, durvalumab + tremelimumab + chemo)	CheckMate 9LA[46], POSEIDON[47]	More immune toxicity with CTLA-4; benefit smaller; chemotherapy alone acceptable if unaffordable
Second line, immunotherapy-naive	After platinum doublet	Nivolumab, pembrolizumab (PD-L1 ≥1%) or atezolizumab	CheckMate 017[48], CheckMate 057[49], KEYNOTE-010[50], OAK[51]	Re-using immunotherapy after progression on it is not standard (rechallenge only if ≥6 months off)
Resectable stage II–IIIB	EGFR/ALK negative, fit for surgery	Neoadjuvant chemo + nivolumab, pembrolizumab or durvalumab, then adjuvant antibody (perioperative)	CheckMate 816[21], KEYNOTE-671[22], AEGEAN[23], CheckMate 77T[24]	EGFR- or ALK-positive tumours; ILD (excluded from trials)
Resected stage II–IIIA after adjuvant chemotherapy	No neoadjuvant therapy given	Atezolizumab (PD-L1 ≥1%, ≥5 cm or N+) or pembrolizumab (≥4 cm or N+)	IMpower010[16], PEARLS/KEYNOTE-091[17]	Only after chemotherapy; EGFR/ALK-positive tumours get targeted therapy
Unresectable stage III after chemoradiation	No progression after concurrent CRT	Durvalumab for 12 months, started within about 6 weeks	PACIFIC[12]	EGFR-positive (use osimertinib, LAURA); grade ≥2 radiation pneumonitis
Limited-stage SCLC after chemoradiation	No progression	Durvalumab for up to 2 years	ADRIATIC[52]	Autoimmune disease, poor PS from comorbidity
Extensive-stage SCLC	First line	Atezolizumab or durvalumab with carboplatin–etoposide, then maintenance (± lurbinectedin with atezolizumab)	IMpower133[53], CASPIAN[54], IMforte[55]	Not chosen by PD-L1; avoid if transplant recipient or active severe autoimmune disease

General cautions before any checkpoint inhibitor: active autoimmune disease needing systemic immunosuppression; organ transplant; ongoing high-dose steroids (short courses for brain oedema or nausea are acceptable); ECOG 3–4; interstitial lung disease (case by case); recent or planned EGFR TKI (pneumonitis); pregnancy. Controlled HIV, HBV and HCV are not contraindications. **Baseline:** TSH, free T4, morning cortisol, glucose, liver and kidney tests, blood count, HBV/HCV/HIV, symptom screen for TB (India: low threshold for testing latent or active TB), oxygen saturation; ECG and troponin if cardiac risk.

Table C. Immune-related side effects

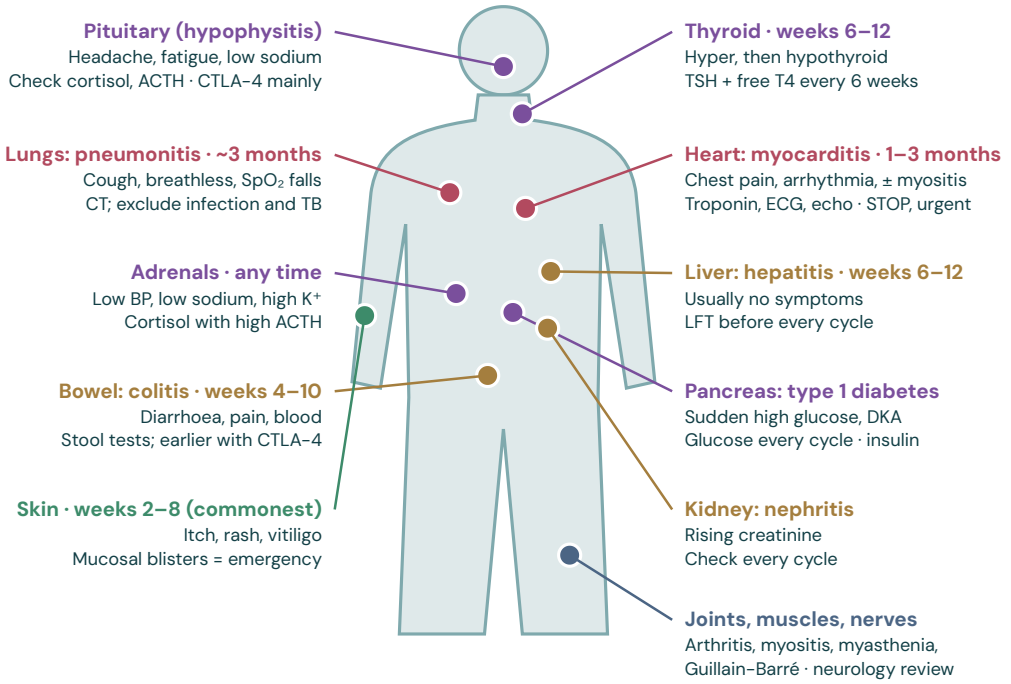

Rose: can be life-threatening, act today · Gold: common, monitor blood tests · Purple: endocrine, often permanent, replace hormone

Timing is typical, not fixed: side effects can appear months after the last dose. Give every patient an immunotherapy alert card.

Figure 15. Immune-related side effects at a glance: where they occur, when they usually appear and the first test to order. Details and management are in Table C.

Immune-related side effect	How it presents · when	Check	Management principle (no doses)
Skin (commonest)	Itch, rash, vitiligo; rarely blistering (SJS/TEN) · weeks 2–8	Extent of body surface; mucosa	Emollients, topical steroids, antihistamines; hold for severe; stop permanently for SJS/TEN
Colitis / diarrhoea	Diarrhoea, pain, blood · weeks 4–10 (earlier with CTLA-4)	Stool tests for infection (C. difficile), CT or colonoscopy if severe	Grade 1: fluids, continue. Grade 2: hold, oral steroids. Grade 3–4: IV steroids; infliximab or vedolizumab if no response in 2–3 days
Hepatitis	Raised ALT/AST, usually asymptomatic · weeks 6–12	LFT every cycle; exclude viral hepatitis, drugs, metastases	Hold for grade 2+; steroids; mycophenolate if refractory (avoid infliximab)
Pneumonitis	Cough, breathlessness, fall in saturation · any time, median ~3 months; higher after thoracic RT	CT chest; exclude infection (including TB) and progression; bronchoscopy if unclear	Grade 1: hold, monitor. Grade 2: hold, steroids. Grade 3–4: stop permanently, IV steroids, admit; add immunosuppressant if refractory
Thyroid	Thyroiditis: brief hyperthyroidism then hypothyroidism · weeks 6–12	TSH, free T4 every 6 weeks	Beta-blocker for the hyper phase; thyroxine replacement; immunotherapy usually continues
Hypophysitis (mainly CTLA-4)	Headache, fatigue, low sodium; low ACTH and cortisol, central hypothyroidism	Morning cortisol, ACTH, TSH/T4, MRI pituitary	Replace hydrocortisone first, then thyroxine; lifelong replacement often needed; sick-day rules
Primary adrenal insufficiency	Fatigue, hypotension, low sodium, high potassium	Cortisol with high ACTH	Hydrocortisone ± fludrocortisone; emergency IV steroids if in crisis

Immune-related side effect	How it presents · when	Check	Management principle (no doses)
Type 1 diabetes	Sudden hyperglycaemia, diabetic ketoacidosis	Glucose every cycle; ketones, C-peptide	Insulin (steroids do not help); immunotherapy can continue when controlled
Myocarditis (rare, can be fatal)	Chest pain, breathlessness, arrhythmia, often with myositis or myasthenia · first 1–3 months	Troponin, ECG, echo, cardiac MRI; CK	Stop permanently; high-dose IV steroids urgently; cardiology; further immunosuppression if needed
Neurological	Myasthenia, Guillain-Barré, encephalitis, neuropathy	Neurology review, MRI, LP as needed	Hold or stop; steroids; IVIG or plasma exchange for myasthenia or Guillain-Barré
Kidney (nephritis)	Rising creatinine	Exclude other causes; urine	Hold for grade 2+; steroids
Joints, eyes, blood	Arthritis, uveitis, cytopenias	Rheumatology or ophthalmology review	NSAIDs or steroids for arthritis; urgent eye review for uveitis
T-cell engager (tarlatamab)	Cytokine release syndrome (fever, low BP, hypoxia) and neurotoxicity (confusion, dysphasia) · first doses	Temperature, BP, saturation, neurological checks during monitored doses	Supportive care, tocilizumab and steroids by grade; hold or stop by severity

Rules of thumb: grade 1 — usually continue and watch; grade 2 — hold until grade 1 or less, steroids for most organs; grade 3 — hold, high-dose steroids, consider stopping; grade 4 — stop permanently (except endocrine problems controlled by replacement). Taper steroids slowly over at least 4–6 weeks; give PJP prophylaxis and gastric protection on prolonged high-dose steroids; endocrine deficiencies are usually permanent. Side effects can appear months after the last dose: patients should carry an immunotherapy alert card.

Table D. Managing common targeted-therapy side effects

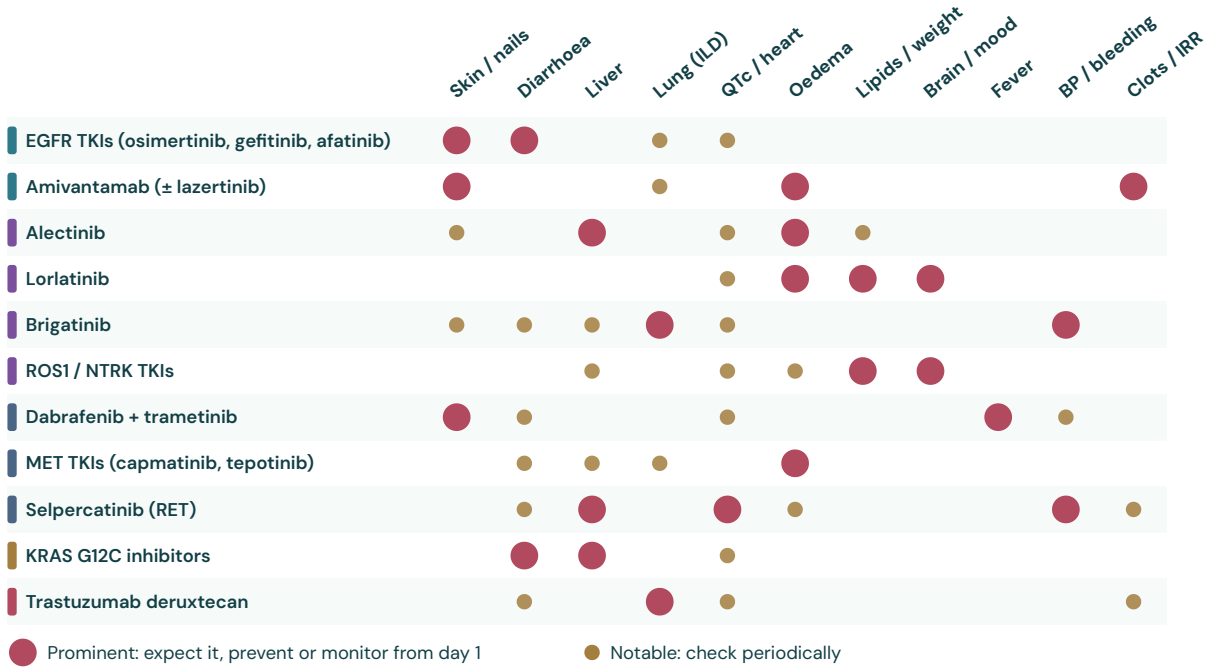

All TKIs: check drug interactions (rifampicin lowers levels; with lorlatinib it can cause severe liver injury), and ask about new cough or breathlessness.

Figure 16. Which targeted drug causes what. Large rose dots are side effects to expect and plan for; small gold dots are worth periodic checks. Management is in Table D.

Side effect	Typical drugs	Practical management (no doses)
Acneiform rash, dry skin	EGFR TKIs, amivantamab	Start emollients and sunscreen from day 1; oral doxycycline or minocycline prophylaxis with amivantamab; topical steroid; dose interruption for severe
Paronychia	EGFR TKIs, amivantamab	Avoid nail trauma; antiseptic soaks; topical steroid–antibiotic; treat infection
Diarrhoea	Afatinib, other EGFR TKIs, adagrasib, sotorasib, zongertinib	Loperamide early, fluids; hold for grade 3; check for infection
Interstitial lung disease	Osimertinib, other EGFR TKIs, trastuzumab deruxtecan, telisotuzumab vedotin, brigatinib (early), MET TKIs	New cough or breathlessness → hold, CT, exclude infection; stop permanently if drug-induced and significant; steroids for moderate–severe
QTc prolongation	Osimertinib, adagrasib, selpercatinib, crizotinib, taletrectinib	Baseline and periodic ECG; correct potassium and magnesium; avoid other QT-prolonging drugs (some antiemetics, antibiotics, antifungals)
Hepatotoxicity	Selpercatinib, taletrectinib, sotorasib (especially after immunotherapy), crizotinib, gefitinib	LFT every 2 weeks for 2–3 months, then monthly; hold and resume at lower intensity
Oedema, low albumin	Capmatinib, tepotinib, amivantamab, alectinib, lorlatinib	Compression, leg elevation; diuretics help little; dose interruption
Lipids, weight, mood	Lorlatinib	Lipids at baseline and every few months; statin; ask about mood, sleep and cognition; dose reduction often resolves CNS effects
Raised CPK, myalgia	Alectinib, brigatinib, binimetinib	CK checks in the first months; hold for symptomatic or very high CK
Fever	Dabrafenib + trametinib	Hold both at the first fever and restart when settled; antipyretics; consider steroid prophylaxis for recurrent episodes
Hypertension, bleeding	Selpercatinib, pralsetinib, ramucirumab, bevacizumab	BP control before and during treatment; avoid anti-VEGF drugs with haemoptysis or central cavitating tumours
Venous thromboembolism	Amivantamab + lazertinib	Prophylactic anticoagulation for the first months
Vision changes	Crizotinib (light trails), MEK inhibitors (serous retinopathy), brigatinib	Usually mild; eye review for persistent changes
Drug interactions	Most TKIs (CYP3A metabolism)	**Rifampicin** (TB treatment) markedly lowers TKI levels and with lorlatinib can cause severe liver injury: discuss with the TB team (rifabutin-based or non-rifamycin regimens). Proton-pump inhibitors reduce absorption of gefitinib, erlotinib and some others. Check every new prescription, including herbal products.

07 Management algorithms

These decision paths pull together sections 02–06. Colours: teal for early or driver-positive paths, purple for locally advanced or driver-negative, rose for unresectable or PD-L1-low paths.

ALGORITHM 1

Non-metastatic NSCLC (stage I–III)

Suspected lung cancer: contrast CT → biopsy that stages → histology, *EGFR*/*ALK*/PD-L1 (NGS if possible) → PET-CT, brain MRI (stage II+), EBUS for nodes → lung function → tumour board

STAGE I (N0)

Fit → surgery first: lobectomy, or segmentectomy if peripheral ≤2 cm (outer third, nodes negative on frozen section) + nodal dissection

Unfit or declines → SBRT (tissue first if possible); ILD → favour sublobar surgery

pT ≤4 cm, N0 → surveillance

Upstaged (>4 cm or pN+) → adjuvant chemo → IO, or osimertinib / alectinib / selpercatinib if *EGFR* / *ALK* / *RET*

Positive margin → re-resect or postoperative RT

RESECTABLE II–III (N0–1, SELECTED SINGLE-STATION N2)

Biomarkers first (do not start IO before *EGFR*/*ALK*)

No driver → chemo-IO × 3–4 → surgery → IO up to 1 year

EGFR+ / ALK+ / RET+ → surgery → adjuvant osimertinib, alectinib or selpercatinib

Re-check lung function after induction · surgery-first then adjuvant therapy is acceptable · R1 → re-resect or PORT

Pancoast → induction chemoradiation → surgery

UNRESECTABLE III (BULKY / MULTI-STATION N2, N3, T4)

Concurrent chemoradiation (about 60 Gy, 6 weeks)

Frail → sequential chemo then RT, or RT alone

No driver → durvalumab 12 months

EGFR+ → osimertinib until progression

ALK+ → no durvalumab; discuss ALK TKI

CT every 3 months in year 1; distinguish pneumonitis from progression

All patients: smoking cessation from the first visit; tumour board before treatment; lung-sparing surgery when oncologically adequate. Confirm PET-positive nodes with EBUS before calling a tumour unresectable.

ALGORITHM 2

Metastatic NSCLC

New stage IV: tissue + NGS (DNA + RNA; plasma ctDNA if tissue is scant) · PD-L1 (22C3) · brain MRI · bone health · early palliative care

ACTIONABLE DRIVER

EGFR → osimertinib ± chemo, or amivantamab + lazertinib (gefitinib + chemo if cost-limited)

ALK → alectinib, lorlatinib or brigatinib

ROS1 → taletrectinib / repotrectinib · **RET · MET ex14 · BRAF** → matched TKI · **NTRK** → TRK inhibitor or chemo-IO

KRAS G12C · HER2 mut · NRG1 → chemo-IO first; targeted drug next (zongertinib may come earlier for HER2)

Progression → re-biopsy or ctDNA

Oligoprogression → local therapy, continue TKI

Systemic → chemo ± amivantamab; small-cell transformation → platinum–etoposide

NO DRIVER: PD-L1 ≥50%

Pembrolizumab, atezolizumab or cemiplimab alone

Bulky, rapid or symptomatic → chemo-IO

Up to 2 years of immunotherapy

Progression → platinum doublet; IO rechallenge only if ≥6 months off treatment

NO DRIVER: PD-L1 <50%

Chemo-immunotherapy

Non-squamous → platinum–pemetrexed + pembrolizumab → pemetrexed maintenance

Squamous → carboplatin–(nab-)paclitaxel + pembrolizumab

PS 2 / elderly → single agent or carboplatin doublet; IO unaffordable → platinum doublet alone

Progression → pemetrexed (if unused) or docetaxel ± ramucirumab; HER2/c-MET protein → targeted ADC

All patients: oligometastatic disease → consider consolidative radiotherapy or surgery · brain metastases → SRS (or TKI first if EGFR/ALK and asymptomatic) · bone metastases → bone-modifying agent · PS 3–4 without a driver → best supportive care.

08 Survivorship, follow-up & reducing recurrence

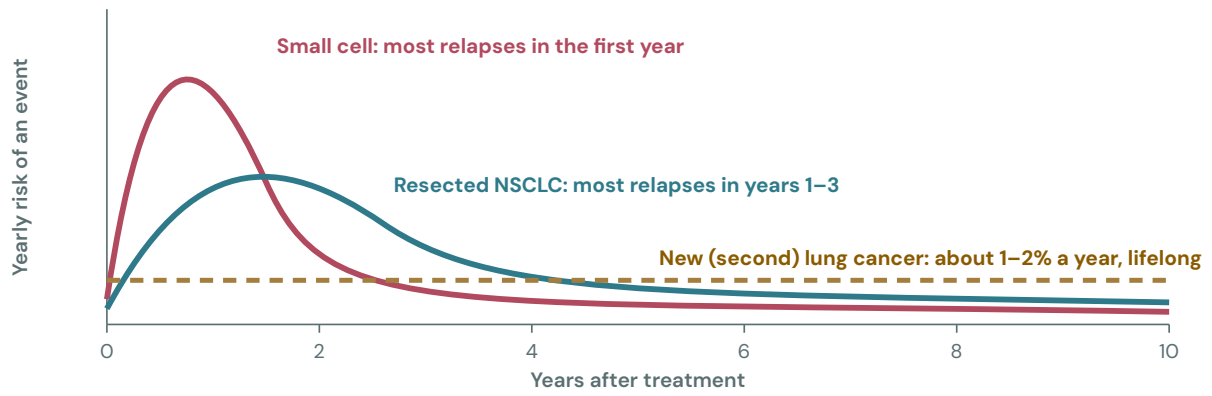

Figure 17. When relapses happen, and when new cancers appear (illustrative shape, not to scale). Early follow-up looks for relapse; later follow-up looks for a new lung cancer, which is why stopping smoking and yearly CT continue.

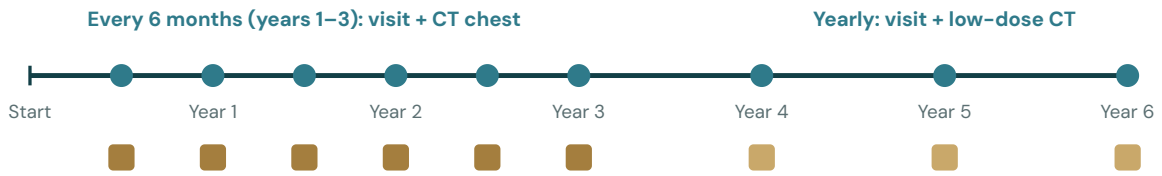

Clinic visit: symptoms, weight, smoking status, late effects, thyroid and cortisol after immunotherapy

CT chest (contrast in years 1–3 if high risk); then low-dose CT once a year

Not routine when well: PET-CT, tumour markers (CEA, CYFRA 21-1), bone scan, brain MRI in NSCLC.
Small cell: closer review (every 2–3 months in year 1); brain MRI every 3 months in year 1 if no PCI was given.

Figure 18. A simple follow-up rhythm (NCCN, ESMO). After SBRT or chemoradiation, fibrosis can mimic relapse on CT: compare with earlier scans and biopsy before calling recurrence.

Follow-up protocol (NCCN, ESMO)

What	How often	Notes
History and examination	Every 6 months for 2–3 years, then yearly; every 2–3 months in year 1 for small cell	Symptoms, weight, smoking status, breathlessness, late effects
CT chest (including the adrenals)	Every 6 months for at least 2 years (2–3 years; contrast preferred), then yearly; low-dose CT beyond 5 years	After SBRT or chemoradiation, fibrosis evolves for up to 2 years: compare serial scans; PET or biopsy only if growth continues
Brain MRI	Not routine in NSCLC; small cell without PCI: every 3 months in year 1, then every 6 months in year 2	Any headache, seizure or focal deficit at any time
PET-CT, tumour markers (CEA, CYFRA 21-1), bone scan	**Not** routine when well	Investigate symptoms promptly instead
Thyroid and adrenal function	Every 6–12 weeks during immunotherapy, and when symptomatic after	Endocrine immune effects can appear months after the last dose

What	How often	Notes
Lung function and rehabilitation	After surgery or chemoradiation, and if breathless	Pulmonary rehabilitation helps; treat COPD optimally
Vaccines	Yearly influenza; pneumococcal; others as per national guidance	Avoid live vaccines during active immunosuppression

Reducing recurrence and second cancers

- **Stop smoking (cigarettes, bidis, hookah)**: continued smoking after diagnosis worsens survival, surgical complications and radiotherapy toxicity, and drives second cancers. Offer varenicline or nicotine replacement plus counselling; India's National Tobacco Quitline is **1800-11-2356** (toll-free).
- Reduce household biomass smoke (LPG under PMUY, ventilated kitchens) for the patient and family.
- **Second primary lung cancer** occurs at about 1–2% a year after resection, for life: this is why yearly low-dose CT continues beyond 5 years. In one large cohort, stopping smoking cut the risk of a second primary by more than 80% (Aredo et al.[56]); continued smoking after early-stage treatment roughly doubles recurrence and death.
- **No pill prevents lung cancer**: vitamins, beta-carotene (harmful in smokers), selenium, retinoids, aspirin and inhaled steroids have all failed or are unproven. Consider stopping oestrogen–progestin menopausal therapy after a diagnosis.
- Complete the planned adjuvant or consolidation therapy; check adherence to oral TKIs at every visit and discuss cost early so treatment is not abandoned.
- **TB in India**: reactivation can occur during immunotherapy or steroids for immune toxicity. A new cavity, effusion or nodule needs sputum NAAT and tissue, not an automatic label of progression.
- Physical activity, nutrition (watch for cachexia), mental health support and return to work are part of survivorship care. Survivors often live with pain, breathlessness, fatigue, poor sleep and low mood: ask about them. Share care with the family doctor, who manages COPD, diabetes and heart disease.

Late effects to look for

- Radiation pneumonitis (1–6 months after radiotherapy) versus immune pneumonitis versus infection: CT pattern, timing and bronchoscopy decide; steroids for moderate pneumonitis.
- Oesophageal stricture, cardiac disease after thoracic radiotherapy, post-thoracotomy pain, reduced exercise capacity.
- Neurocognitive change after PCI; hypothyroidism and adrenal insufficiency after immunotherapy; neuropathy after taxanes or platinum.

SHARE WITH PATIENTS: AFTER TREATMENT

Plain-language myth pages written for patients and families. Send them from the clinic to reinforce what you discussed.

- 🖨 Telugu–English handout: stop tobacco (తెలుగు · English)
- Once you have lung cancer, there is no point in stopping smoking?
- Once lung cancer treatment is finished, follow-up scans aren't needed?
- If I stop smoking, my lung cancer risk becomes zero straight away?

09 Landmark trials

Figure 19. How to read a survival curve (illustrative). Use the absolute gap at a fixed time and overall survival, not the median or PFS alone, when weighing benefit against toxicity and cost.

- **NLST**[3] and **NELSON**[4]: does low-dose CT screening of heavy smokers save lives? Yes: lung cancer deaths fell by about a fifth. → Screening works in high-risk smokers with a proper nodule pathway; Indian data are lacking.
- **IPASS**[57]: gefitinib versus chemotherapy in Asian never- or light-smoking adenocarcinoma. Gefitinib was better only in *EGFR*-mutant tumours and worse in wild-type. → The biomarker, not the clinical profile, selects targeted therapy.
- **FLAURA**[27], **FLAURA2**[29] and **MARIPOSA**[31]: how should *EGFR*-mutant disease be treated first? Osimertinib beat older TKIs, and both intensified regimens (adding chemotherapy, or amivantamab–lazertinib) now improve overall survival at the cost of more toxicity. → Choose by disease burden (brain, L858R), fitness, toxicity and cost.
- **PACIFIC**[12]: durvalumab after chemoradiation for unresectable stage III. Five-year survival rose by about 10 percentage points. → Standard consolidation, except for *EGFR*/*ALK*-positive tumours (**LAURA**[13] for *EGFR*).
- **ADAURA**[18]: osimertinib after resection of *EGFR*-mutant stage IB–IIIA. Disease-free and then overall survival improved (5-year 88% vs 78%). → Test *EGFR* in every resected NSCLC.
- **CheckMate 816**[21] and **KEYNOTE-671**[22]: chemo-immunotherapy before (and after) surgery. Pathological complete responses rose from a few percent to about a fifth; event-free survival improved, and KEYNOTE-671 improved overall survival. → Resectable stage II–III without a driver is now a perioperative disease.

10 Practice pearls & pitfalls

- Never start a “therapeutic trial” of antituberculous treatment for a mass, collapse or unexplained effusion. Prove TB, or get tissue.
- Plan one biopsy for diagnosis, stage and biomarkers: prefer EBUS of a node or a core biopsy, keep stains to a minimum, and ask the pathologist to protect tissue for NGS.
- Waiting 1–2 weeks for *EGFR*/*ALK* results is almost always safe and avoids giving immunotherapy to driver-positive patients (little benefit, and pneumonitis with later osimertinib).
- Read benefit in absolute terms and separate progression-free from overall survival, especially when weighing intensified regimens against cost. In India, generic TKIs, gefitinib + chemotherapy, patient-assistance programmes and Ayushman Bharat PM-JAY packages can make the difference between treatment and abandonment: discuss cost on day one.
- A patient bed-bound from *EGFR*- or *ALK*-positive cancer can walk again within weeks of a TKI: do not deny testing because of poor performance status.
- PET-positive does not mean malignant in India: confirm nodes with EBUS and nodules with biopsy before denying or offering curative treatment.
- Patients with ILD are at high risk of lung cancer and of treatment toxicity: favour lung-sparing surgery and decide on radiotherapy and immunotherapy with a pulmonologist.
- Biopsy the suspected metastasis (node, liver, adrenal, bone), not the primary, when advanced disease is likely: one procedure then diagnoses and stages.
- Repeat spirometry and DLCO after neoadjuvant chemo-immunotherapy before the surgeon finalises the resection.
- If more than 8 weeks pass between staging and treatment, or new symptoms appear, re-stage before starting.
- Previous TB raises lung cancer risk. A TB survivor with new symptoms needs CT and tissue, not another course of TB drugs.
- Ask every patient about biomass smoke and every smoker about bidis; record pack-years. Advise against LDCT for never-smokers outside research.

11 Case vignettes: lines of management

Six cases, written for postgraduates and practising clinicians. Read the presentation, decide on stage, workup and plan, then open the line of management. No doses are given; durations follow the evidence.

CASE 1 **Adenocarcinoma · EGFR · metastatic**

Never-smoker treated for "TB" for five months

46 years, never smoked | cT2b N2 M1c2 (stage IVB) | EGFR exon 19 deletion | 3 small brain metastases

A 46-year-old schoolteacher who has never smoked had a cough and weight loss. A chest X-ray showed a left upper zone opacity and she was started on antituberculous treatment without sputum testing. After 5 months she is more breathless, has lost 7 kg and has a left effusion. She cooked on a wood stove until 10 years ago.

Before you open the answer: what is the stage, what must be done before treatment, and what is the plan?

1. **STOP AND PROVE**
   Sputum NAAT negative. Contrast CT: 4.5 cm left upper lobe mass, subcarinal and left paratracheal nodes, small pleural nodules and effusion, two liver lesions. Pleural fluid: exudate, ADA low, cytology adenocarcinoma (TTF-1 positive) with a cell block.
2. **BIOMARKERS**
   NGS on the cell block: *EGFR* exon 19 deletion; PD-L1 TPS 30%. While waiting, the effusion is drained; no chemotherapy or immunotherapy is started.
3. **STAGING**
   Brain MRI: three asymptomatic metastases under 1 cm. Bone health baseline. ECOG 2 (improving after drainage).
4. **FIRST LINE**
   Osimertinib, with platinum–pemetrexed added if she is fit and agrees (FLAURA2; brain metastases favour the combination); amivantamab–lazertinib is the alternative. If cost is prohibitive: gefitinib + pemetrexed–carboplatin (Tata Memorial trial). Brain radiotherapy is deferred, with MRI at 6–8 weeks.
5. **SUPPORTIVE**
   Indwelling pleural catheter or pleurodesis if it refills; zoledronic acid only if bone metastases; early palliative care; counselling about rash, diarrhoea and paronychia.
6. **AT PROGRESSION**
   ctDNA or re-biopsy: *MET* amplification, *EGFR* C797S or small-cell transformation change the next step; platinum–pemetrexed ± amivantamab otherwise.

TEACHING POINTS

- Empirical TB treatment without microbiological proof cost five months; a low-ADA exudate was the clue.
- Pleural fluid cell blocks are often enough for NGS.
- Do not start immunotherapy while *EGFR* results are pending.

See: Sections 02, 04, 06 · Algorithm 2 · FLAURA2[29], MARIPOSA[31], Tata Memorial trial[32]

CASE 2 **NSCLC · stage I**

A 1.8 cm nodule in a farmer with COPD

68 years, 40 pack-years (bidis) | cT1b N0 (IA2) | FEV_1 48%, DLCO 45%

A 68-year-old farmer with COPD has a new 1.8 cm spiculated solid nodule in the right upper lobe on a CT done for breathlessness. It was not present on a CT 2 years ago. He has had TB in the past.

Before you open the answer: what is the stage, what must be done before treatment, and what is the plan?

1. **WORKUP**
   PET-CT: nodule SUV 7; no nodal or distant uptake. CT-guided core biopsy (rather than assuming cancer, given past TB): adenocarcinoma, *EGFR* and *ALK* negative.
2. **FITNESS**
   Predicted post-operative FEV_1 and DLCO about 40%: stair climb and exercise testing show moderate risk. Pulmonary rehabilitation and smoking cessation started.
3. **OPTIONS**
   If he becomes fit enough: segmentectomy with nodal sampling (peripheral, ≤2 cm, N0: JCOG0802). If not, or if he prefers: SBRT in 3–5 sessions, with local control around 90%.
4. **DECISION**
   After tumour board and discussion, SBRT. No adjuvant systemic therapy for stage IA.
5. **FOLLOW-UP**
   CT at 3 months, then every 6 months for 3 years, then yearly. Post-SBRT fibrosis changes shape for 1–2 years: compare serial scans before calling recurrence.

TEACHING POINTS

- A growing nodule in a past-TB patient still needs tissue; PET cannot separate granuloma from cancer.
- Segmentectomy is a proven option for small peripheral tumours; SBRT for inoperable patients.
- Smoking cessation and rehabilitation change both fitness and outcome.

See: Sections 03, 05 · Algorithm 1 · JCOG0802[8], CALGB 140503[9]

CASE 3 NSCLC · resectable stage III

Single-station N2 adenocarcinoma, driver-negative

59 years, ex-smoker | cT2a N2a (IIIA, 9th edition) | EGFR/ALK negative · PD-L1 60%

A 59-year-old ex-smoker has a 3.5 cm right lower lobe mass. PET shows uptake in subcarinal nodes only. ECOG 0, good lung function.

Before you open the answer: what is the stage, what must be done before treatment, and what is the plan?

1. **STAGE THE MEDIASTINUM**
   EBUS-TBNA: station 7 positive for adenocarcinoma; 4R and 4L negative. Brain MRI clear. cT2a N2a M0.
2. **BIOMARKERS FIRST**
   NGS: no actionable driver; PD-L1 60%. Had *EGFR* been positive, upfront surgery then adjuvant osimertinib would be preferred over immunotherapy.
3. **NEOADJUVANT**
   Platinum doublet + PD-1/PD-L1 antibody for 3–4 cycles (CheckMate 816 / KEYNOTE-671 / AEGEAN / CheckMate 77T); restage with CT.
4. **SURGERY**
   Lobectomy with mediastinal lymph node dissection. Pathological complete response in about one in five patients.
5. **ADJUVANT**
   Continue the antibody for up to a year (perioperative design). No postoperative radiotherapy for R0 pN2 (Lung ART).

6 **IF NOT RESECTABLE**

Had EBUS shown multi-station bulky N2: concurrent chemoradiation, then durvalumab (PACIFIC).

TEACHING POINTS

- Invasive mediastinal staging separates single-station from multi-station N2 and decides surgery versus chemoradiation.
- Driver testing comes before any immunotherapy, even in early-stage disease.
- Response in the surgical specimen is a strong marker of long-term outcome.

See: Sections 03, 05, 06 · Algorithm 1 · CheckMate 816[21], KEYNOTE-671[22], Lung ART[14]

CASE 4 NSCLC · unresectable stage III

Bulky squamous cancer with contralateral nodes

63 years, 45 pack-years | cT3 N3 (IIIC) | Squamous · PD-L1 20%

A 63-year-old smoker with haemoptysis has a 6 cm left upper lobe mass with left paratracheal, subcarinal and right lower paratracheal nodes. ECOG 1, FEV_1 70%.

Before you open the answer: what is the stage, what must be done before treatment, and what is the plan?

1 **CONFIRM STAGE**

EBUS: 4R positive (contralateral, N3) and 7 positive. PET: no distant disease. Brain MRI clear. Unresectable stage IIIC.

2 **BIOMARKERS**

Squamous in a heavy smoker: *EGFR*/*ALK* testing optional but reasonable; PD-L1 20%.

3 **DEFINITIVE TREATMENT**

Concurrent chemoradiation: about 60 Gy in 30 daily sessions over 6 weeks with a platinum doublet. Plan transport and nutrition with the family; oesophagitis peaks in weeks 3–5.

4 **CONSOLIDATION**

No progression on CT → durvalumab for 12 months, started within 6 weeks (PACIFIC). Watch for pneumonitis (cough, breathlessness, fever) during months 1–6.

5 **FOLLOW-UP**

CT every 3 months in year 1. Smoking cessation throughout.

TEACHING POINTS

- N3 disease is not surgical but is curable with chemoradiation and consolidation.
- Concurrent beats sequential chemoradiation when the patient can tolerate it.
- For an *EGFR*-mutant tumour in the same setting, osimertinib replaces durvalumab (LAURA).

See: Sections 05, 06 · Algorithm 1 · PACIFIC[12], PACIFIC 5-year[26], LAURA[13]

CASE 5 NSCLC · metastatic · no driver

High PD-L1, bone metastases, limited budget

61 years, smoker | cT2b N1 M1c1 (IVB) | No driver · PD-L1 80%

A 61-year-old auto-rickshaw driver who smokes 20 bidis a day has back pain. Imaging shows a right upper lobe mass and several spinal metastases without cord compression. ECOG 1.

Before you open the answer: what is the stage, what must be done before treatment, and what is the plan?

1 **DIAGNOSIS**

CT-guided biopsy of the lung mass: adenocarcinoma. NGS (through a patient-assistance programme): no driver; PD-L1 TPS 80%. Brain MRI clear.

2 **LOCAL**

Single-session radiotherapy to the painful vertebra; zoledronic acid after dental check; calcium and vitamin D.

3 **SYSTEMIC**

Pembrolizumab alone (KEYNOTE-024): no chemotherapy needed for most PD-L1 ≥50% tumours. If immunotherapy is not affordable: platinum–pemetrexed, then pemetrexed maintenance.

4 **MONITORING**

Thyroid tests and symptoms every cycle; scans every 9–12 weeks; up to 2 years of treatment.

5 **THROUGHOUT**

Smoking cessation (quitline 1800-11-2356); early palliative care for pain and family planning.

TEACHING POINTS

- PD-L1 ≥50% without a driver is the one setting where immunotherapy alone is a standard first line.
- Single-session radiotherapy relieves bone pain as well as longer courses.
- Discuss cost and access on day one; there is a valid chemotherapy-only pathway.

See: Sections 04, 06 · Algorithm 2 · KEYNOTE-024[39], KEYNOTE-189[41], Temel trial[45]

CASE 6 **Adenocarcinoma · ALK · metastatic**

Young man with an effusion and seizures

34 years, never smoked | M1c2 (IVB) | ALK fusion (IHC + NGS)

A 34-year-old engineer had a right pleural effusion 3 months ago, labelled tuberculous on a lymphocytic exudate without microbiology. He now presents with a seizure.

Before you open the answer: what is the stage, what must be done before treatment, and what is the plan?

1 **WORKUP**

MRI brain: four metastases, one with oedema. CT: right lower lobe primary, pleural nodules, liver lesions. Pleural biopsy: adenocarcinoma; *ALK* IHC strongly positive, fusion confirmed by NGS.

2 **IMMEDIATE**

Steroids and antiepileptic drug; neurosurgical and radiation oncology review.

3 **FIRST LINE**

Lorlatinib or alectinib, both with high brain activity (CROWN, ALEX). Radiosurgery can often be deferred with MRI at 6–8 weeks; treat the symptomatic lesion if it does not respond.

4 **SIDE EFFECTS**

Lorlatinib: lipids, weight, oedema, mood and sleep change. Alectinib: CPK, bilirubin, photosensitivity. Check interactions with antiepileptic drugs (enzyme inducers lower TKI levels: prefer levetiracetam).

5 **LATER**

At progression, re-biopsy for resistance mutations (G1202R → lorlatinib if not used). Many patients live for years: plan work, fertility and family.

TEACHING POINTS

- A young never-smoker with a “TB” effusion needs cytology and tissue.
- *ALK* IHC (D5F3) is a reliable, affordable screen.
- Brain-penetrant ALK inhibitors can control brain metastases without upfront radiotherapy.

See: Sections 02, 04, 06 · Algorithm 2 · CROWN[35], ALEX[34]

12 References & guidelines

- NCCN Clinical Practice Guidelines in Oncology: Non-Small Cell Lung Cancer; Small Cell Lung Cancer; Lung Cancer Screening (current versions).
- ESMO Clinical Practice Guidelines: early and locally advanced NSCLC; oncogene-addicted and non-oncogene-addicted metastatic NSCLC (living guidelines); small cell lung cancer.
- ASCO living guidelines: therapy for stage IV NSCLC with and without driver alterations.
- IASLC/UICC TNM Classification of Lung Cancer, 9th edition; IASLC lymph node map.
- CAP/IASLC/AMP guideline on molecular testing for lung cancer; IASLC guidance on liquid biopsy.
- Fleischner Society 2017 guidelines for incidental pulmonary nodules; ACR Lung-RADS v2022; USPSTF 2021 lung cancer screening recommendation.
- ICMR consensus document for the management of lung cancer; National TB Elimination Programme (NTEP) guidance on microbiological confirmation of TB.
- ACCP guidelines on the diagnosis and staging of lung cancer; ESTS guidance on preoperative mediastinal staging; ASTRO guidelines on SBRT and palliative thoracic radiotherapy.
- Cross-checked in October 2026 against current evidence summaries (UpToDate topic reviews on diagnosis and staging, biopsy modalities, preoperative lung function, systemic therapy in resectable NSCLC, genotype-directed therapy, targeted-drug lung toxicity, relapsed small cell lung cancer, TNM 9th edition, pathology, stage I–III and advanced NSCLC, small cell lung cancer, brain and oligometastases, ILD, multiple primaries, screening reports, risk factors, never-smokers, women and survivorship). All text is written in our own words and cites primary sources.
- Trial names above link to PubMed searches for the primary publications.

Core trials cited on this page (57)

Journal, year, volume and first page; each links to the PubMed record by exact citation.

NUMBERED IN ORDER OF FIRST CITATION IN THE TEXT

1. **ILCCO prior lung disease**: Brenner DR, Boffetta P, Duell EJ, et al. Previous lung diseases and lung cancer risk: a pooled analysis from the International Lung Cancer Consortium. *Am J Epidemiol* 2012;176:573. PubMed Risk factors and prevention
2. **WHI oestrogen-progestin and lung cancer**: Chlebowski RT, Schwartz AG, Wakelee H, et al. Oestrogen plus progestin and lung cancer in postmenopausal women (Women's Health Initiative trial): a post-hoc analysis of a randomised controlled trial. *Lancet* 2009;374:1243. PubMed Risk factors and prevention
3. **NLST**: National Lung Screening Trial Research Team; Aberle DR, Adams AM, Berg CD, et al. Reduced lung-cancer mortality with low-dose computed tomographic screening. *N Engl J Med* 2011;365:395. PubMed Screening
4. **NELSON**: de Koning HJ, van der Aalst CM, de Jong PA, et al. Reduced lung-cancer mortality with volume CT screening in a randomized trial. *N Engl J Med* 2020;382:503. PubMed Screening
5. **TRUST**: Pérol M, Li W, Pennell NA, et al. Taletrectinib in ROS1+ non-small cell lung cancer: TRUST. *J Clin Oncol* 2025;43:1920. PubMed Metastatic NSCLC: targeted therapy
6. **LIBRETTO-432**: Wu YL, Hochmair M, Yang Y, et al. Selpercatinib in early-stage RET fusion-positive non-small-cell lung cancer. *N Engl J Med* 2026;395:660. PubMed Stage I–III systemic therapy
7. **Beamion LUNG-1**: Heymach JV, Ruiter G, Ahn MJ, et al. Zongertinib in previously treated HER2-mutant non-small-cell lung cancer. *N Engl J Med* 2025;392:2321. PubMed Metastatic NSCLC: targeted therapy
8. **JCOG0802**: Saji H, Okada M, Tsuboi M, et al. Segmentectomy versus lobectomy in small-sized peripheral non-small-cell lung cancer (JCOG0802/WJOG4607L): a multicentre, open-label, phase 3, randomised, controlled, non-inferiority trial. *Lancet* 2022;399:1607. PubMed Surgery and radiotherapy
9. **CALGB 140503**: Altorki N, Wang X, Kozono D, et al. Lobar or sublobar resection for peripheral stage IA non-small-cell lung cancer. *N Engl J Med* 2023;388:489. PubMed Surgery and radiotherapy

10. **Gomez trial**: Gomez DR, Tang C, Zhang J, et al. Local consolidative therapy vs. maintenance therapy or observation for patients with oligometastatic non-small-cell lung cancer: long-term results of a multi-institutional, phase II, randomized study. *J Clin Oncol* 2019;37:1558. PubMed Surgery and radiotherapy
11. **SABR-COMET**: Palma DA, Olson R, Harrow S, et al. Stereotactic ablative radiotherapy versus standard of care palliative treatment in patients with oligometastatic cancers (SABR-COMET): a randomised, phase 2, open-label trial. *Lancet* 2019;393:2051. PubMed Surgery and radiotherapy
12. **PACIFIC**: Antonia SJ, Villegas A, Daniel D, et al. Durvalumab after chemoradiotherapy in stage III non-small-cell lung cancer. *N Engl J Med* 2017;377:1919. PubMed Stage I–III systemic therapy
13. **LAURA**: Lu S, Kato T, Dong X, et al. Osimertinib after chemoradiotherapy in stage III EGFR-mutated NSCLC. *N Engl J Med* 2024;391:585. PubMed Stage I–III systemic therapy
14. **Lung ART**: Le Péchoux C, Pourel N, Barlesi F, et al. Postoperative radiotherapy versus no postoperative radiotherapy in patients with completely resected non-small-cell lung cancer and proven mediastinal N2 involvement (Lung ART, IFCT 0503): an open-label, randomised, phase 3 trial. *Lancet Oncol* 2022;23:104. PubMed Surgery and radiotherapy
15. **LACE**: Pignon JP, Tribodet H, Scagliotti GV, et al. Lung adjuvant cisplatin evaluation: a pooled analysis by the LACE Collaborative Group. *J Clin Oncol* 2008;26:3552. PubMed Stage I–III systemic therapy
16. **IMpower010**: Felip E, Altorki N, Zhou C, et al. Adjuvant atezolizumab after adjuvant chemotherapy in resected stage IB–IIIA non-small-cell lung cancer (IMpower010): a randomised, multicentre, open-label, phase 3 trial. *Lancet* 2021;398:1344. PubMed Stage I–III systemic therapy
17. **PEARLS/KEYNOTE-091**: O'Brien M, Paz-Ares L, Marreaud S, et al. Pembrolizumab versus placebo as adjuvant therapy for completely resected stage IB–IIIA non-small-cell lung cancer (PEARLS/KEYNOTE-091): an interim analysis of a randomised, triple-blind, phase 3 trial. *Lancet Oncol* 2022;23:1274. PubMed Stage I–III systemic therapy
18. **ADAURA**: Wu YL, Tsuboi M, He J, et al. Osimertinib in resected EGFR-mutated non-small-cell lung cancer. *N Engl J Med* 2020;383:1711. PubMed Stage I–III systemic therapy
19. **ADAURA OS**: Tsuboi M, Herbst RS, John T, et al. Overall survival with osimertinib in resected EGFR-mutated NSCLC. *N Engl J Med* 2023;389:137. PubMed Stage I–III systemic therapy
20. **ALINA**: Wu YL, Dziadziuszko R, Ahn JS, et al. Alectinib in resected ALK-positive non-small-cell lung cancer. *N Engl J Med* 2024;390:1265. PubMed Stage I–III systemic therapy
21. **CheckMate 816**: Forde PM, Spicer J, Lu S, et al. Neoadjuvant nivolumab plus chemotherapy in resectable lung cancer. *N Engl J Med* 2022;386:1973. PubMed Stage I–III systemic therapy
22. **KEYNOTE-671**: Wakelee H, Liberman M, Kato T, et al. Perioperative pembrolizumab for early-stage non-small-cell lung cancer. *N Engl J Med* 2023;389:491. PubMed Stage I–III systemic therapy
23. **AEGEAN**: Heymach JV, Harpole D, Mitsudomi T, et al. Perioperative durvalumab for resectable non-small-cell lung cancer. *N Engl J Med* 2023;389:1672. PubMed Stage I–III systemic therapy
24. **CheckMate 77T**: Cascone T, Awad MM, Spicer JD, et al. Perioperative nivolumab in resectable lung cancer. *N Engl J Med* 2024;390:1756. PubMed Stage I–III systemic therapy
25. **NeoADAURA**: He J, Tsuboi M, Weder W, et al. Neoadjuvant osimertinib for resectable EGFR-mutated non-small cell lung cancer. *J Clin Oncol* 2025;43:2875. PubMed Stage I–III systemic therapy
26. **PACIFIC 5-year**: Spigel DR, Faivre-Finn C, Gray JE, et al. Five-year survival outcomes from the PACIFIC trial: durvalumab after chemoradiotherapy in stage III non-small-cell lung cancer. *J Clin Oncol* 2022;40:1301. PubMed Stage I–III systemic therapy
27. **FLAURA**: Soria JC, Ohe Y, Vansteenkiste J, et al. Osimertinib in untreated EGFR-mutated advanced non-small-cell lung cancer. *N Engl J Med* 2018;378:113. PubMed Metastatic NSCLC: targeted therapy
28. **FLAURA OS**: Ramalingam SS, Vansteenkiste J, Planchard D, et al. Overall survival with osimertinib in untreated, EGFR-mutated advanced NSCLC. *N Engl J Med* 2020;382:41. PubMed Metastatic NSCLC: targeted therapy
29. **FLAURA2**: Planchard D, Jänne PA, Cheng Y, et al. Osimertinib with or without chemotherapy in EGFR-mutated advanced NSCLC. *N Engl J Med* 2023;389:1935. PubMed Metastatic NSCLC: targeted therapy
30. **FLAURA2 OS**: Jänne PA, Planchard D, Kobayashi K, et al. Survival with osimertinib plus chemotherapy in EGFR-mutated advanced NSCLC. *N Engl J Med* 2026;394:27. PubMed Metastatic NSCLC: targeted therapy
31. **MARIPOSA**: Cho BC, Lu S, Felip E, et al. Amivantamab plus lazertinib in previously untreated EGFR-mutated advanced NSCLC. *N Engl J Med* 2024;391:1486. PubMed Metastatic NSCLC: targeted therapy
32. **Tata Memorial gefitinib + chemotherapy**: Noronha V, Patil VM, Joshi A, et al. Gefitinib versus gefitinib plus pemetrexed and carboplatin chemotherapy in EGFR-mutated lung cancer. *J Clin Oncol* 2020;38:124. PubMed Metastatic NSCLC: targeted therapy
33. **PAPILLON**: Zhou C, Tang KJ, Cho BC, et al. Amivantamab plus chemotherapy in NSCLC with EGFR exon 20 insertions. *N Engl J Med* 2023;389:2039. PubMed Metastatic NSCLC: targeted therapy

34. **ALEX**: Peters S, Camidge DR, Shaw AT, et al. Alectinib versus crizotinib in untreated ALK-positive non-small-cell lung cancer. *N Engl J Med* 2017;377:829. PubMed Metastatic NSCLC: targeted therapy
35. **CROWN**: Shaw AT, Bauer TM, de Marinis F, et al. First-line lorlatinib or crizotinib in advanced ALK-positive lung cancer. *N Engl J Med* 2020;383:2018. PubMed Metastatic NSCLC: targeted therapy
36. **LIBRETTO-431**: Zhou C, Solomon B, Loong HH, et al. First-line selpercatinib or chemotherapy and pembrolizumab in RET fusion-positive NSCLC. *N Engl J Med* 2023;389:1839. PubMed Metastatic NSCLC: targeted therapy
37. **CodeBreaK 200**: de Langen AJ, Johnson ML, Mazieres J, et al. Sotorasib versus docetaxel for previously treated non-small-cell lung cancer with KRAS G12C mutation: a randomised, open-label, phase 3 trial. *Lancet* 2023;401:733. PubMed Metastatic NSCLC: targeted therapy
38. **DESTINY-Lung01**: Li BT, Smit EF, Goto Y, et al. Trastuzumab deruxtecan in HER2-mutant non-small-cell lung cancer. *N Engl J Med* 2022;386:241. PubMed Metastatic NSCLC: targeted therapy
39. **KEYNOTE-024**: Reck M, Rodríguez-Abreu D, Robinson AG, et al. Pembrolizumab versus chemotherapy for PD-L1-positive non-small-cell lung cancer. *N Engl J Med* 2016;375:1823. PubMed Metastatic NSCLC: immunotherapy and supportive care
40. **KEYNOTE-024 5-year**: Reck M, Rodríguez-Abreu D, Robinson AG, et al. Five-year outcomes with pembrolizumab versus chemotherapy for metastatic non-small-cell lung cancer with PD-L1 tumor proportion score ≥ 50%. *J Clin Oncol* 2021;39:2339. PubMed Metastatic NSCLC: immunotherapy and supportive care
41. **KEYNOTE-189**: Gandhi L, Rodríguez-Abreu D, Gadgeel S, et al. Pembrolizumab plus chemotherapy in metastatic non-small-cell lung cancer. *N Engl J Med* 2018;378:2078. PubMed Metastatic NSCLC: immunotherapy and supportive care
42. **KEYNOTE-407**: Paz-Ares L, Luft A, Vicente D, et al. Pembrolizumab plus chemotherapy for squamous non-small-cell lung cancer. *N Engl J Med* 2018;379:2040. PubMed Metastatic NSCLC: immunotherapy and supportive care
43. **KEYNOTE-042**: Mok TSK, Wu YL, Kudaba I, et al. Pembrolizumab versus chemotherapy for previously untreated, PD-L1-expressing, locally advanced or metastatic non-small-cell lung cancer (KEYNOTE-042): a randomised, open-label, controlled, phase 3 trial. *Lancet* 2019;393:1819. PubMed Metastatic NSCLC: immunotherapy and supportive care
44. **REVEL**: Garon EB, Ciuleanu TE, Arrieta O, et al. Ramucirumab plus docetaxel versus placebo plus docetaxel for second-line treatment of stage IV non-small-cell lung cancer after disease progression on platinum-based therapy (REVEL): a multicentre, double-blind, randomised phase 3 trial. *Lancet* 2014;384:665. PubMed Metastatic NSCLC: immunotherapy and supportive care
45. **Temel early palliative care**: Temel JS, Greer JA, Muzikansky A, et al. Early palliative care for patients with metastatic non-small-cell lung cancer. *N Engl J Med* 2010;363:733. PubMed Metastatic NSCLC: immunotherapy and supportive care
46. **CheckMate 9LA**: Paz-Ares L, Ciuleanu TE, Cobo M, et al. First-line nivolumab plus ipilimumab combined with two cycles of chemotherapy in patients with non-small-cell lung cancer (CheckMate 9LA): an international, randomised, open-label, phase 3 trial. *Lancet Oncol* 2021;22:198. PubMed Metastatic NSCLC: immunotherapy and supportive care
47. **POSEIDON**: Johnson ML, Cho BC, Luft A, et al. Durvalumab with or without tremelimumab in combination with chemotherapy as first-line therapy for metastatic non-small-cell lung cancer: the phase III POSEIDON study. *J Clin Oncol* 2023;41:1213. PubMed Metastatic NSCLC: immunotherapy and supportive care
48. **CheckMate 017**: Brahmer J, Reckamp KL, Baas P, et al. Nivolumab versus docetaxel in advanced squamous-cell non-small-cell lung cancer. *N Engl J Med* 2015;373:123. PubMed Metastatic NSCLC: immunotherapy and supportive care
49. **CheckMate 057**: Borghaei H, Paz-Ares L, Horn L, et al. Nivolumab versus docetaxel in advanced nonsquamous non-small-cell lung cancer. *N Engl J Med* 2015;373:1627. PubMed Metastatic NSCLC: immunotherapy and supportive care
50. **KEYNOTE-010**: Herbst RS, Baas P, Kim DW, et al. Pembrolizumab versus docetaxel for previously treated, PD-L1-positive, advanced non-small-cell lung cancer (KEYNOTE-010): a randomised controlled trial. *Lancet* 2016;387:1540. PubMed Metastatic NSCLC: immunotherapy and supportive care
51. **OAK**: Rittmeyer A, Barlesi F, Waterkamp D, et al. Atezolizumab versus docetaxel in patients with previously treated non-small-cell lung cancer (OAK): a phase 3, open-label, multicentre randomised controlled trial. *Lancet* 2017;389:255. PubMed Metastatic NSCLC: immunotherapy and supportive care
52. **ADRIATIC**: *N Engl J Med* 391:1313. PubMed Other studies cited in the text
53. **IMpower133**: *N Engl J Med* 379:2220. PubMed Other studies cited in the text
54. **CASPIAN**: *Lancet* 394:1929. PubMed Other studies cited in the text
55. **IMforte**: *Lancet* 405:2129. PubMed Other studies cited in the text
56. **Smoking and second primary lung cancer**: Aredo JV, Luo SJ, Gardner RM, et al. Tobacco smoking and risk of second primary lung cancer. *J Thorac Oncol* 2021;16:968. PubMed Risk factors and prevention
57. **IPASS**: Mok TS, Wu YL, Thongprasert S, et al. Gefitinib or carboplatin–paclitaxel in pulmonary adenocarcinoma. *N Engl J Med* 2009;361:947. PubMed Metastatic NSCLC: targeted therapy

Educational summary for health professionals, written in our own words from current guidelines and primary trials. No drug doses are given.

> Verify current guidelines, Indian regulatory approvals and individual patient factors before treatment decisions.